

## Early Results of Fenestrated Endovascular Repair of Juxtarenal Aortic Aneurysms in the United Kingdom

On behalf of the British Society for Endovascular Therapy and the Global Collaborators on Advanced Stent-Graft Techniques for Aneurysm Repair (GLOBALSTAR) Registry

*Circulation*. 2012;125:2707-2715

doi: 10.1161/CIRCULATIONAHA.111.070334

*Circulation* is published by the American Heart Association, 7272 Greenville Avenue, Dallas, TX 75231

Copyright © 2012 American Heart Association, Inc. All rights reserved.

Print ISSN: 0009-7322. Online ISSN: 1524-4539

The online version of this article, along with updated information and services, is located on the World Wide Web at:

<http://circ.ahajournals.org/content/125/22/2707>

**Permissions:** Requests for permissions to reproduce figures, tables, or portions of articles originally published in *Circulation* can be obtained via RightsLink, a service of the Copyright Clearance Center, not the Editorial Office. Once the online version of the published article for which permission is being requested is located, click Request Permissions in the middle column of the Web page under Services. Further information about this process is available in the [Permissions and Rights Question and Answer](#) document.

**Reprints:** Information about reprints can be found online at:  
<http://www.lww.com/reprints>

**Subscriptions:** Information about subscribing to *Circulation* is online at:  
<http://circ.ahajournals.org/subscriptions/>

## Early Results of Fenestrated Endovascular Repair of Juxtarenal Aortic Aneurysms in the United Kingdom

On behalf of the British Society for Endovascular Therapy and the Global Collaborators on Advanced Stent-Graft Techniques for Aneurysm Repair (GLOBALSTAR) Registry

**Background**—Fenestrated endovascular repair of abdominal aortic aneurysms has been proposed as an alternative to open surgery for juxtarenal and pararenal abdominal aortic aneurysms. At present, the evidence base for this procedure is predominantly limited to single-center or single-operator series. The aim of this study was to present nationwide early results of fenestrated endovascular repair in the United Kingdom.

**Methods and Results**—All patients who underwent fenestrated endovascular repair between January 2007 and December 2010 at experienced institutions in the United Kingdom (>10 procedures) were retrospectively studied by use of the GLOBALSTAR database. Site-reported data relating to patient demographics, aneurysm morphology, procedural details, and outcome were recorded. Data from 318 patients were obtained from 14 centers. Primary procedural success was achieved in 99% (316/318); perioperative mortality was 4.1%, and intraoperative target vessel loss was observed in 5 of 889 target vessels (0.6%). The early reintervention (<30 days) rate was 7% (22/318). There were 11 deaths during follow-up; none were aneurysm-related. Survival by Kaplan–Meier analysis was 94% (SE 0.01), 91% (0.02), and 89% (0.02) at 1, 2, and 3 years, respectively. Freedom from target vessel loss was 93% (0.02), 91% (0.02), and 85% (0.06), and freedom from late secondary intervention (>30 days) was 90% (0.02), 86% (0.03), and 70% (0.08) at 1, 2, and 3 years.

**Conclusions**—In this national sample, fenestrated endovascular repair has been performed with a high degree of technical and clinical success. Late survival and target vessel patency are satisfactory. These results support continued use and evaluation of this technique for juxtarenal aneurysms, but illustrate the need for a more robust evidence base. (*Circulation*. 2012;125:2707-2715.)

**Key Words:** fenestrated endovascular aneurysm repair ■ juxtarenal aneurysm ■ target vessel  
■ endovascular aneurysm repair ■ fenestration

Data from randomized, controlled trials have demonstrated that endovascular repair (EVAR) of abdominal aortic aneurysms may be performed with lower rates of early mortality and morbidity in comparison with conventional open surgical techniques.<sup>1,2</sup> In recent years, increasingly complex endograft designs, with the incorporation of fenestrations and branches, have been used to treat pararenal, juxtarenal, and thoracoabdominal aneurysms.<sup>3</sup>

### Editorial see p 2684 Clinical Perspective on p 2715

Initial reports from large single-center and single-operator series have suggested that fenestrated endografts may be used to repair juxtarenal aneurysms with a relatively low mortality and morbidity, and with low rates of target vessel loss (usually renal and superior mesenteric arteries).<sup>4,5</sup> These encouraging results must be tempered, however, by the knowledge that most early reports of the technique come from expert and experienced operators who have been in-

involved in the development of complex endograft design. Because the number of fenestrated stent-grafts implanted worldwide has exceeded 3000 cases, it would be appropriate to produce national results to investigate whether single-center experiences are reproduced in wider clinical practice. Fenestrated endovascular repair (f-EVAR) is an exciting innovation, but one which needs careful and robust evaluation according to the Innovation, Development and Exploration, Assessment and Long-term study (IDEAL) protocol, which calls for a 3-stage evaluation of technology.<sup>6</sup> The innovation of f-EVAR and the development of the technique have been well documented. This study falls in the second stage of the protocol, ie, exploration of clinical results, leading into the final stage of long-term evaluation.

The need for high-quality and realistic evaluation of mid- and long-term results of f-EVAR has been highlighted recently by the relatively poor outcomes that have been described for infrarenal EVAR.<sup>7,8</sup> Concerns persist that endovascular techniques have a significant long-term compli-

Received September 27, 2011; accepted April 2, 2012.

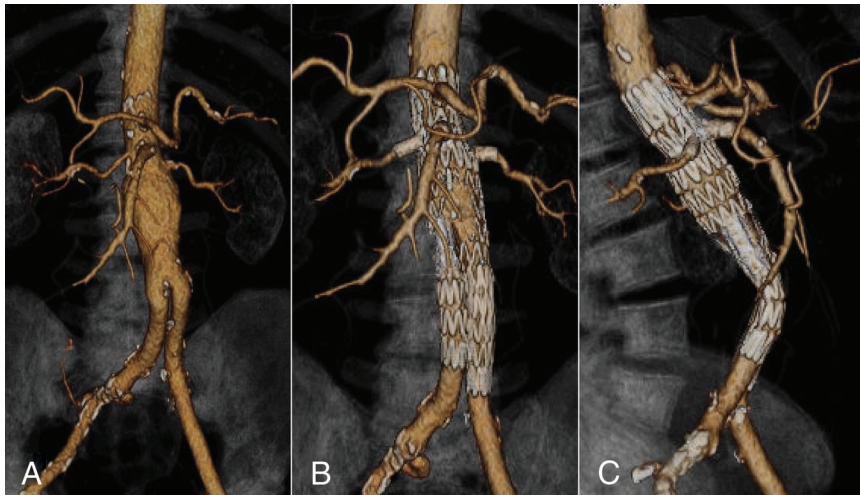
From the Royal Liverpool University Hospital, Liverpool, United Kingdom.

Correspondence to Srinivasa Rao Vallabhaneni, MD, FRCS, EBSQ-Vasc, Consultant Vascular & Endovascular Surgeon, Link 8C, Royal Liverpool University Hospital, Prescot Street, Liverpool, L7 8XP, United Kingdom. E-mail fempop@liv.ac.uk

© 2012 American Heart Association, Inc.

*Circulation* is available at <http://circ.ahajournals.org>

DOI: 10.1161/CIRCULATIONAHA.111.070334



**Figure 1.** A, Volume rendered image of arterial-phase CT showing a juxtarenal aneurysm. Anterior (B) and right lateral (C) views after f-EVAR. The stent-graft could be seen extending into the visceral segment of the aorta with perfusion of the superior mesenteric and both renal arteries maintained via precisely located fenestrations and target vessel stents placed through the fenestrations. Celiac axis is perfused through an unstented scallop. f-EVAR indicates fenestrated endovascular repair.

cation and reintervention rate that lead to continued aneurysm expansion and occasional late rupture. The aim of the present study was to examine early and midterm results of f-EVAR in the United Kingdom by the use of a retrospective analysis of all patients from centers who had performed in >10 procedures.

### Methods

All centers within the United Kingdom that had performed 10 or more f-EVAR procedures at the time of the initiation of the study collaborated to generate this retrospective analysis under the auspices of the British Society for Endovascular Therapy. All patients who underwent f-EVAR between January 2007 and December 2010 were included. Branched thoracoabdominal endovascular procedures were excluded from this analysis. Distinction between branched EVAR and f-EVAR in this study was in accordance with the Society of Vascular Surgery reporting standards on thoracic endovascular aortic repair, which depends on whether or not a gap exists between the stent-graft main body and the target vessel ostium that requires bridging.<sup>9</sup> This distinction was made by the reporting clinicians. The study pertained to institutional experience, and all f-EVAR procedures performed within the collaborating centers during the study period were included. Procedures proctored by specialists that took place outside the collaborating centers were not included. To ensure that all eligible patients were captured, the numbers of f-EVAR devices supplied to the collaborating centers during the study period were obtained from the manufacturer, Cook Medical (Canvey Island, UK), and any discrepancies with enrolled numbers were investigated.

The technique of f-EVAR has been described extensively.<sup>10,11</sup> In brief, a stent-graft main body comprising holes (fenestrations) located exactly to match the target vessel ostia is passed into the aorta and partially unconstrained from the delivery system. The target vessels are then cannulated from within this component via the fenestrations, and target vessel stents are tracked into place. The fenestrated main body is then completely deployed, followed by deployment of target vessel stents. This achieves sealing of the aneurysm at the level of the visceral aorta while preserving blood flow through the aortic branches. Exclusion of the aneurysm is completed with additional modular components extending the stent-graft into the iliac segments (Figure 1).

Data relating to demographics, comorbidity, physiological parameters of the Vascular Physiological and Operative Severity Score for the enUmeration of Mortality and Morbidity (V-POSSUM) risk score, operative and postoperative data, and follow-up data were collected by use of a secure on-line data collection system of the GLOBAL collaborators on advanced Stent-graft Techniques for Aneurysm Repair (GLOBALSTAR) project.<sup>12</sup> Values and events

were site reported, and there was no core laboratory verification. Definitions of comorbid conditions, and complications/phenomena associated with endovascular techniques were in accordance with accepted reporting standards.<sup>9,13</sup> The definition for a target vessel was “a vessel potentially covered by the stent-graft fabric if not for a deliberate mechanism of preservation, when the stent-graft is deployed as intended.” These were counted on intention-to-treat basis in accordance with the reporting standards, and all scallops and fenestrations were considered indicative of target vessels. Events within 30 days of the primary procedure were referred to as “early” events, and events after that period were termed “late” events.

### Statistical Analysis

Completeness of data reporting was indicated with the results. SPSS software (IBM Corporation), R language (GNU General Public License), and Excel (Microsoft) were used for statistical analysis. Quantitative data were analyzed to present mean, median, and range. Estimated open surgical predicted mortality of the cohort was calculated according to established V-POSSUM methodology. Events and complications noted during late follow-up were subjected to Kaplan–Meier analysis. Patients were censored at the time of death or at the last follow-up. The relationship between the anatomic extent of the f-EVAR and the risk of perioperative death was estimated by a nonlinear logistic regression with related 95% confidence interval. The nonlinearity arises from the fact that the anatomic extent is an ordinal categorical variable. A formal Wald test of the null hypothesis of no effect of anatomic extent on death was conducted to confirm the qualitative results.

## Results

### Patients

A total of 318 patients were enrolled from 14 centers (see Appendix). Eighty-six percent were men, and 14% were women. The mean age was 74 years (range, 47–86; median, 74). The mean aortic aneurysm size (maximum diameter) was 65 mm (range, 46–113; median, 62). The aneurysm size was not reported in 9.1% of the cohort. In patients with aortic diameter smaller than 55 mm, the indication for repair was the presence of a significant iliac aneurysm. Comorbidities and American Society of Anesthesiologists grading recorded are tabulated (Table 1). The number of patients recruited from each center ranged from 11 to 59.

### Operative Details

Cook Zenith fenestrated stent-grafts were successfully implanted in 316 of the 318 patients. In 1 patient, the procedure

**Table 1. Prevalence of Comorbidity in the Cohort and ASA Grading**

Comorbidity	
Diabetes mellitus	13.8
Hypertension	61.6
Ischemic heart disease	46.9
Heart failure	6
Chronic renal failure	13.8
Cerebrovascular disease	8.5
Previous aortic surgery	0.9
ASA grade	
ASA 1	0.6
ASA 2	20.1
ASA 3	51.3
ASA 4	12.6
Unreported	15.4

Values stated are percentages. ASA indicates American Society of Anesthesiologists.

was abandoned because the stent-graft could not be passed through the access segment. In another patient, it was not possible to orient the stent-graft in the desired position. The stent-graft was advanced into the thoracic aorta and parked in a preexisting thoracic endograft. Both patients survived the perioperative period.

The mean duration of operation (data reported in 75%) was 4 hours 31 minutes (range, 1 hour 20 minutes to 12 hours; median, 4 hours). Intraoperative blood loss was a mean of 807 mL (range, 50–7000 mL; median, 500 mL). The target vessel configuration of the f-EVAR was reported in 305 (97%) of the patients (Table 2). There were a total of 889 target vessels, of which 670 (75%) were stented (Table 3). Bare metal stents were used in 63 vessels (Palmaz Genesis, Cordis Corp. in 35; EV3, EV3 Endovascular Inc. in 13; Luminexx, Bard peripheral vascular Inc. in 7; AVE, Medtronic Inc. in 2; Express, Boston Scientific in 1; and unspecified bare stents in 5) and covered stents were used in 529 vessels (Advanta, Atrium Medical in 522; Jostent, Abbott

**Table 2. Configuration of Stent-Graft and Target Vessels**

Target Vessels	Configuration	n
CA+SMA+ Rt and Lt renals	4F	8
	1S 3F	53
	2S 2F	2
CA+SMA+ renal	1S 2F	1
SMA+Rt and Lt renals	3F	48
	1S 2F	114
	2S 1F	6
Rt and Lt renals	1S 1F	13
	2F	44
One renal	1S	4
	1F	12

S indicates scallop; F, fenestration; CA, celiac artery; SMA, superior mesenteric artery; Rt, right; and Lt, left.

**Table 3. Target Vessels**

	S	F	
CA	59 (0)	13 (10)	
SMA	128 (2)	120 (111)	
Rt renal	10 (3)	274 (266)	
Lt renal	4 (1)	281 (277)	
Total	201 (6)	688 (664)	889 (670)

Numbers in parentheses denote stented target vessels. S indicates scallop; F, fenestration; CA, celiac artery; SMA, superior mesenteric artery; Rt, right; and Lt, left.

vascular in 4; and Fluency, Bard peripheral vascular in 3). The stent used was unspecified in the remaining 78 vessels.

Completion angiography was reported in 306 of the 316 patients. All target vessels were recorded to be fully patent at the end of the primary procedure in 296 patients (97%). A single target vessel was lost in 5 patients (1.6% of patients and 0.6% of the target vessels; 4 renal arteries and 1 celiac trunk). One patient had tight stenosis of the right renal artery preoperatively which was occluded on completion. Failure of cannulation resulted in the loss of right renal artery in 2 patients. The mechanism of target vessel loss was not reported in the other 2 patients. The clinical course in the patients with intraoperative target vessel loss was as follows: (1) Right renal artery lost, leading to infarcted kidney, but no significant rise in creatinine was observed. (2) Celiac axis occlusion. Hepatic malperfusion syndrome was recognized. This patient did not survive. (3) Right renal artery lost. Died of myocardial infarction. (4) Left renal artery lost. This patient also needed coverage of external iliac artery for rupture and a femoropopliteal bypass. Renal failure noted. Patient did not survive. (5) It was not possible to cannulate the right renal artery. This vessel was lost, but endoleak was noted from the fenestration. Significant rise in creatinine was documented. It was not possible to ascertain the contributory role of target vessel loss toward perioperative death in these patients.

A compromise was noted in at least 1 target vessel in another 5 patients (1.6% of patients and 0.6% of target vessels). Three patients with filling defects in the renal arteries were treated conservatively, and the renal arteries were patent at subsequent follow-up. In 1 patient, both the renal arteries were compromised on the completion angiogram. The left was stented but appearances were unsatisfactory, and it was not possible to cannulate the right. This patient required permanent dialysis in the postoperative period. Endoleaks as recorded at the primary procedure and adjuvant intraoperative procedures are tabulated (Tables 4 and 5, respectively). Adjuvant procedures were required in 16.4% of cases. The mean hospital stay was 9 days (range, 1–100 days; median, 6 days). Only 120 patients (38%) required admission to intensive care facilities postoperatively. When intensive care unit was used, the mean duration of stay was 3.7 days (range, 1–38 days; median, 2).

### Perioperative Mortality

A total of 11 patients died within 30 days of the primary procedure, and an additional 2 patients died during the

**Table 4. Endoleaks as Recorded at Completion of the Primary Procedure**

Type of Endoleak	n (%)
Proximal type 1	14 (4.6)
Distal type 1	3 (1)
Type 3 (target vessel junction)	2 (0.7)
Type 3 (between bodies)	2 (0.7)
Type 3 (between limbs)	1 (0.3)
All type 3	5 (1.7)
Type 2	22 (7.2)

admission for the primary f-EVAR (one at 33 days and another at 45 days) leading to a total perioperative mortality of 4.1%.

To examine the relationship between the anatomic extent of the f-EVAR and the risk of perioperative death, the patients were assigned into 3 groups according to the level of the highest fenestration zone. Group 1 was defined by patients with renal fenestrations alone, group 2 by patients with fenestrations/scallop for the superior mesenteric artery, and group 3 by grafts incorporating the celiac trunk. Group 1 contained 73 patients, of whom 2 died (2.7%); group 2 comprised 168 patients, of whom 5 died (2.9%); and group 3 included 64 patients, of whom 6 died (9.4%). Nonlinear logistic regression analysis of the relationship between incremental extent and risk of death revealed that, although greater anatomic extent was associated with greater risk of perioperative death, this difference failed to reach statistical significance ( $\chi^2$  on 2 degrees of freedom 4.65,  $P=0.098$ ).

A total of 97 significant complications were recorded in a total of 52 patients, some of whom died (Table 6). Twenty patients underwent early reintervention after the primary f-EVAR within 30 days, which are illustrated in Table 7.

### Spinal Cord Ischemia

In this series, 5 patients developed spinal cord ischemia in the postoperative period. In all these patients, no obvious preoperative predisposing factors were identified, prophylactic spinal drains were not used, and the f-EVAR procedure itself was considered uneventful. In 4 of 5 patients, the endograft extended to the celiac trunk. Spinal cord ischemia developed at the following times in the postoperative period: 2 patients immediately postoperatively, and one each at 24 hours, 48 hours, and 3 days. All patients were treated with a spinal protocol that included insertion of a spinal drain and blood pressure manipulation. One patient made a full recovery after correction of anemia and hypotension, 2 patients made a partial recovery, and 2 patients made no recovery.

### Target Vessel Patency

Overall, target vessel loss was reported in 7 left renal arteries, 4 right renal arteries, 2 celiac trunks, and 1 superior mesenteric artery. Kaplan–Meier analysis of target vessel patency is shown in Figure 2. Between the operation and 4 months, target vessel loss was noted in 9 patients (left renal artery in 2, celiac artery and left renal in 1, right renal in 3, both renal arteries and the stent-graft in 1, celiac artery in 1; the target vessel lost was not specified in 1 patient). After 4 months and

**Table 5. Planned and Unplanned Adjuvant Procedures Undertaken at the Time of the Primary f-EVAR**

Access management
Common femoral artery endarterectomy±patch (n=3)
Iliac conduit for access (n=3)
Angioplasty of access segment (n=2)
Ruptured EIA covered by limb (TFLE 12–90)
Endoleak management
Balloon molding of the proximal main body (n=3)
6-cm proximal cuff inserted. One renal artery preserved.
Palmaz stent insertion
Left renal stent recatheterized and ballooned to treat a modular connection endoleak
Insertion of body extension (ESBE 32–39) to treat type I endoleak
Target vessel management
PTA of celiac axis stenosis
SMA stent displaced distally, new stent deployed
Thrombus noted in SMA, stent inserted
Coil embolization of bleeding SMA branch
Left renal artery perforation, restent using Atrium (n=2)
Left renal stent reballoon to correct a stenosis, possibly caused by deformation by the proximal main body
Nitrate and additional heparin into right renal artery to improve compromised circulation
Bilateral injection of isosorbide mononitrate and tissue plasminogen activator for thromboembolic episode of renal arteries
SMA dissected requiring extension of stents distally (n=2)
AV fistula left kidney caused by guidewire, treated by coil embolization
Additional
Insertion of a bare stent to treat or prevent a limb kink (n=12)
Fem-fem crossover bypass (n=3)
Internal iliac embolization (n=4)
Left iliac occlusion due to malpositioning of left iliac limb, requiring conversion to AUI+fem-fem crossover bypass
Inability to cannulate contralateral limb requiring conversion to AUI, iliac occlude and crossover bypass
Temporary axillofemoral bypass to maintain intraoperative lower limb perfusion
Maneuvers to solve difficulty in retrieving the top-cap lead to SMA stent thrombosis requiring thrombosuction and restenting

f-EVAR indicates fenestrated endovascular repair; EIA, external iliac artery; TFLE, Cook Medical Iliac leg; ESBE, Cook Medical Main body extension; PTA, percutaneous transluminal angioplasty; SMA, superior mesenteric artery; AV, atrioventricular; AUI, aortouniiliac; and fem-fem, femorofemoral.

within 9 months, 1 patient was noted to have fracture and occlusion of the superior mesenteric artery stent. Between 9 and 18 months after the procedure, a further 3 target vessels, all left renal arteries, were noted to have been lost. Between 18 and 30 months into follow-up, 1 unstented renal artery was lost. Between 30 and 43 months of follow-up, there was another patient in whom target vessel loss was documented.

### Follow-Up

Patients were followed up according to local protocols within each institution. Arterial phase CT scans, plain radiography,

**Table 6. Significant Postoperative Complications Reported**

Cardiovascular	n
MI	8
Cardiac failure	5
Dysrhythmia	7
Hypertension	1
Hypotension	2
Respiratory	
Pneumonia	8
Exacerbation of COAD	3
Gastrointestinal	
GI ischemia	5
Prolonged ileus	1
Gastric ulcer	1
Diarrhea	1
Sepsis	
Sepsis or septicemia	6
Groin wound infection	4
Mycotic aneurysm popliteal from septic embolus	1
Urinary tract infection	6
Pyrexia of unidentified origin	1
Renal	
Infarction of kidney	4
Urinary retention	2
Renal failure	11
Ureteric obstruction	1
Bleeding	
Groin hematoma	5
Heparin-induced thrombocytopenia	1
Neurological	
TIA	3
Spinal ischemia	5
Ischemic	
Lower limb ischemia	3
Brachial artery pseudoaneurysm	1
Brachial embolectomy	1

MI indicates myocardial infarction; COAD, chronic obstructive airways disease; and TIA, transient ischemic attack.

duplex ultrasound examination, and blood tests for urea electrolytes and blood counts were the mainstay of surveillance. CT scan was performed before discharge routinely in some, but not all hospitals. For patients who had a technically satisfactory f-EVAR, the most common surveillance protocol was as follows: baseline plain radiography before discharge and annually; arterial phase CT and blood tests at 1, 6, and 12 months and annually thereafter.

The median follow-up in this series was 6 months. Overall survival is given as a Kaplan–Meier table in Figure 3. A total of 11 deaths were reported during follow-up; none of them were aneurysm related. Complications such as stent-graft migration, limb occlusion, and structural distortion of target vessel stent were noted. A number of late secondary interventions were also reported (Table 8). These events are reported by Kaplan–Meier

**Table 7. Reintervention After the f-EVAR Within 30 Days**

Access site
Groin reexploration for hematoma.
Target vessel
Pinching of the right renal artery. Successful angioplasty.
Acute renal failure from loss of renal arteries. Successful hepatic to left renal bypass.
Kinked SMA stent. Successful restenting.
Failure to stent right renal artery during the primary procedure. Successful secondary stenting.
Bleeding from left renal branch. Successful coil embolization of branch preserving main renal (n=3).
Occluded right renal stent. Successful recanalization and restenting.
Thrombosed SMA and CA stents. Unsuccessful endovascular recanalization. Laparotomy for infarcted gut. Death.
Endoleak
Type 3 endoleak. Successful relining.
Type 1 endoleak, SMA stent stenosis. Successful abolition of endoleak and restenting of SMA.
Other
Insertion of cardiac pacemaker for bradyarrhythmia
Insertion of ureteric stent for hydronephrosis
Surgical repair of brachial artery pseudoaneurysm
Removal of infected femorofemoral bypass conduit
Femoropopliteal bypass for ischemic leg
Iliac embolectomy and angioplasty for ischemic leg
Postoperative stent-graft infection treated by coverage of visceral segment and extra-anatomic bypass to SMA and chimney to right renal. Death.
Bowel resection and stoma for ischemic gut. Survived.

f-EVAR indicates fenestrated endovascular repair; SMA, superior mesenteric artery; and CA, celiac artery.

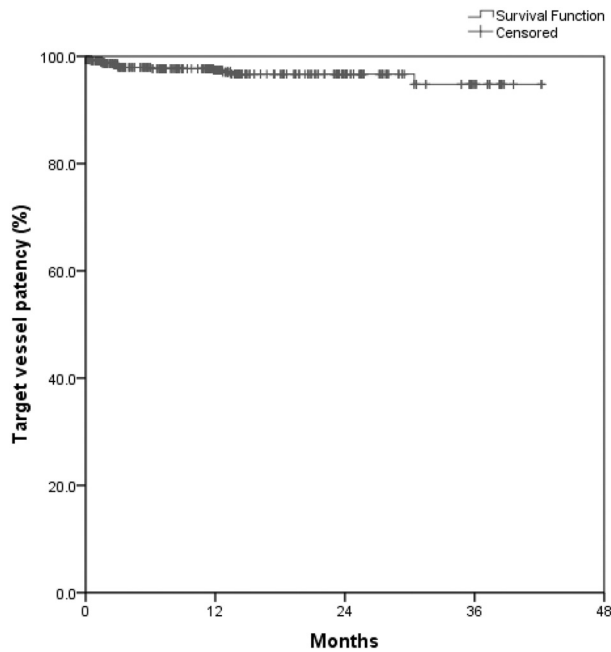
analysis in Figures 4 through 7. Estimated cumulative proportions of freedom from each of these complications and standard error are given in the Kaplan–Meier tables.

### V-POSSUM Scoring System and Predicted Risk of Open Repair

V-POSSUM physiological severity score was reported for at least 8 of the 12 parameters in 246 patients in whom the risk of perioperative death was estimated by use of V-POSSUM scoring for open surgical repair. For risk estimation purposes, the missing parameters in this group of patients were considered to be in the normal range in accordance with V-POSSUM calculations. A total of 27 perioperative deaths (11%) were estimated for open repair in the cohort of patients in the present study that underwent f-EVAR.

### Discussion

Hypothetically there should be a reduction in perioperative death when endovascular techniques are used for repair of juxtarenal/pararenal aneurysms in preference to open surgery. Published series of f-EVAR have reported low perioperative mortality rates from large single-center or single-operator studies.<sup>5,7</sup> Clearly, it is important to define whether the benefit of complex endovascular techniques are transferable

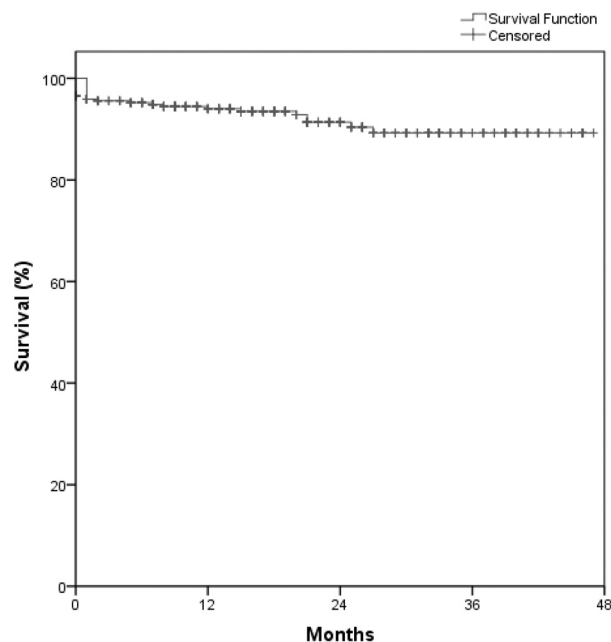


Time (months)	0	3	6	12	24	36	42
n (TV) at risk	889	573	472	365	149	40	3
Cum Survival (%)	99	98	98	97	97	95	95
Std err (Cum.surv.)	0.00	0.00	0.01	0.01	0.01	0.02	0.02

**Figure 2.** Kaplan–Meier analysis of target vessel (TV) patency. Cum indicates cumulative; surv., survival.

from specialized centers to the more general vascular community, and whether these techniques offer a durable solution to complex aneurysm morphology.

The present series represents the largest cohort of patients undergoing f-EVAR to date. All centers within the United



Time (months)	0	3	6	12	24	36	45
n at risk	318	284	273	215	110	38	12
Cum. Survival (%)	96	95	95	94	91	89	89
Std err (Cum.surv.)	0.01	0.01	0.01	0.01	0.02	0.02	0.02

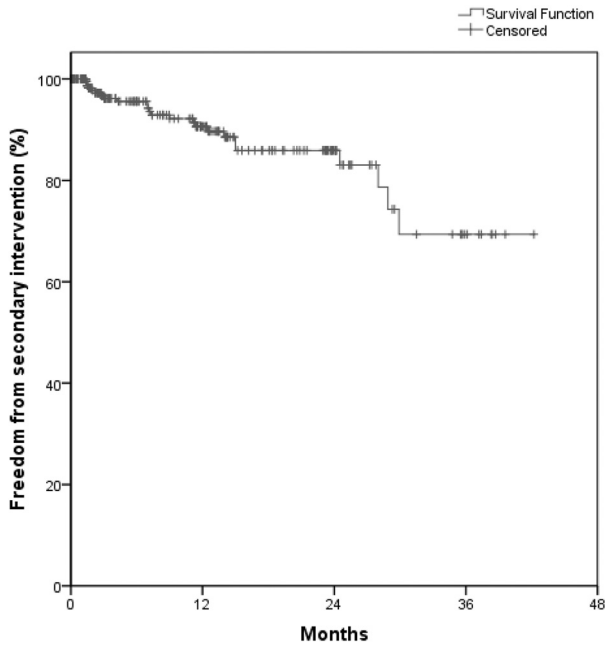
**Figure 3.** Kaplan–Meier analysis of overall survival. Cum indicates cumulative; surv., survival.

**Table 8. Late Reintervention after f-EVAR**

Time Since f-EVAR, min	Secondary Intervention Notes
2	Aortogram, right renal angiogram, and right renal artery stent angioplasty.
2	Angiography and attempt to recanalize right renal artery, unsuccessful. Separate event: angiography to investigate left renal, no intervention.
2 and 5	Extension of celiac stent. Insertion of SMA stent.
2 and 13	Angioplasty of renal stents to treat suspected type modular connection endoleak. Repeat angiography and extension of right renal stent with Atrium stent.
3	Restenosis of right iliac bare stent and CFA with rest pain. Underwent covered stenting of EIA and below-knee fem-pop bypass
3	Right iliac limb extension
4	Surgical drainage of infected hematoma left kidney.
7	Angiogram right renal artery and insertion of 7 mm × 18 mm Palmaz Genesis
7	Insertion of left ureteric stent to relieve hydronephrosis caused by involvement of the left ureter with perineurysmal fibrosis
7	Angioplasty of left renal stent stenosis. Angioplasty of right iliac limb stenosis and limb extension.
7	Right renal stent stenosis needed angioplasty
9	Left renal stent fracture and stenosis treated by angioplasty
10	Further Atrium stent placed to secure left renal fenestration. Separate event: femoral endarterectomy and stent insertion into to treat severe claudication right leg.
11 and 25	Left renal stent relined with EV3 stent (at 11 m). The same stent was relined again with Atrium stent (at 25 m).
13	Embolization of type II endoleak.
14	Endoluminal occlusion of the IMA (embolization)
15	Right renal artery angioplasty.
15	Left lower renal artery stented for type II endoleak
25	IMA embolization to abolish a type II endoleak leading to aneurysm enlargement.
28	Extension of right iliac limb to EIA for aneurysmal dilatation of the CIA.
29	Femorofemoral bypass for left iliac limb occlusion.
30	Stent insertion for external compression on celiac axis, apparently unrelated to the fenestrated device

f-EVAR indicates fenestrated endovascular repair; SMA, superior mesenteric artery; EIA, external iliac artery; CFA, common femoral artery; CIA, common iliac artery; IMA, inferior mesenteric artery; and fem-pop, femoropopliteal.

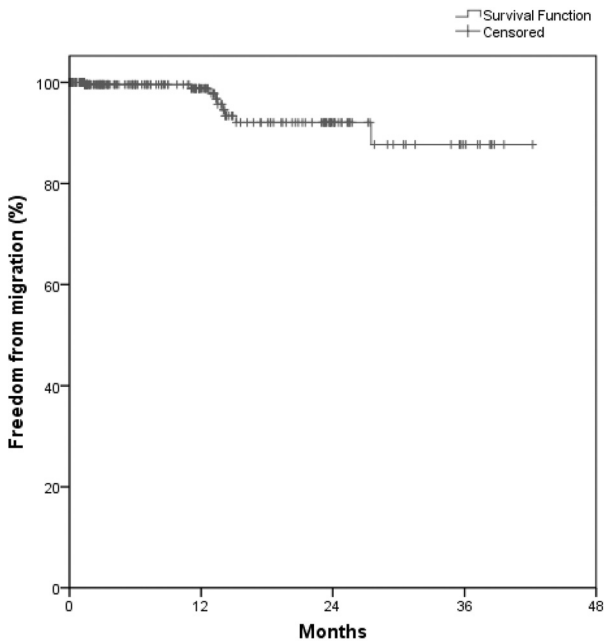
Kingdom who had performed >10 f-EVARs at the time of study initiation, enrolled their patients operated on during the study period in an attempt to eliminate reporting bias. The figure of 10 used to define inclusion of an institution was arbitrary, but was considered to represent the experience level at which proctoring would not usually be required. Centers with less experience were not included to minimize the effect of the initial learning curve. All participating centers have substantial expertise in endovascular techniques, with a



Time (months)	0	3	6	12	24	36	42
n at risk	309	198	161	122	48	12	1
Cum. Freedom (%)	100	97	95	90	86	70	70
Std.Err.(Cum.surv.)	0.00	0.01	0.01	0.02	0.03	0.08	0.08

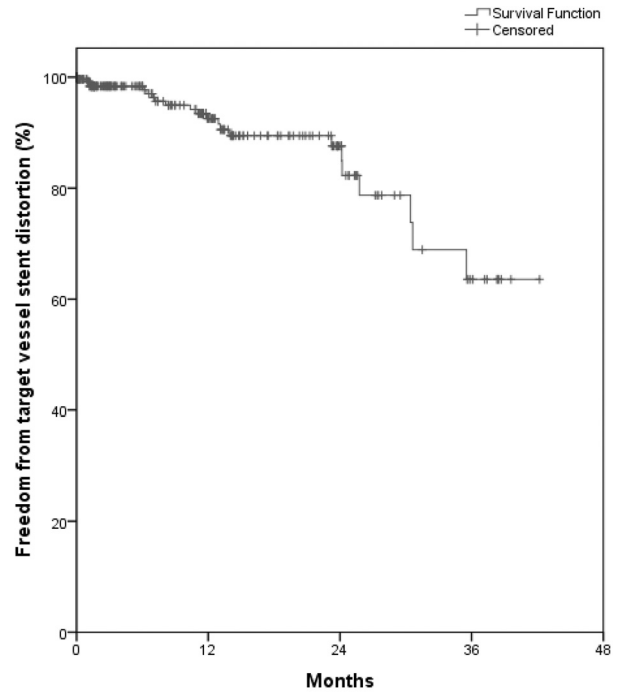
Figure 4. Kaplan-Meier analysis of freedom from late secondary intervention. Cum indicates cumulative; surv., survival.

multidisciplinary approach to f-EVAR comprising both vascular surgeons and interventional radiologists. The total number of f-EVAR procedures that took place in the United Kingdom, but outside the participating centers by the end of the study period, was small, at only 70 spread over 20 centers



Time (months)	0	3	6	12	24	36	42
n at risk	309	199	164	128	51	13	1
Cum. Freedom (%)	100	100	100	99	92	88	88
Std.err.(Cum.surv.)	0.00	0.00	0.00	0.01	0.03	0.05	0.05

Figure 5. Kaplan-Meier analysis of freedom from stent-graft migration. Cum indicates cumulative; surv., survival.



Time (months)	0	3	6	12	24	36	42
n at risk	309	197	162	123	49	13	1
Cum. Freedom (%)	100	98	98	92	87	63	63
Std.Err.(Cum.surv.)	0.00	0.01	0.01	0.02	0.03	0.09	0.09

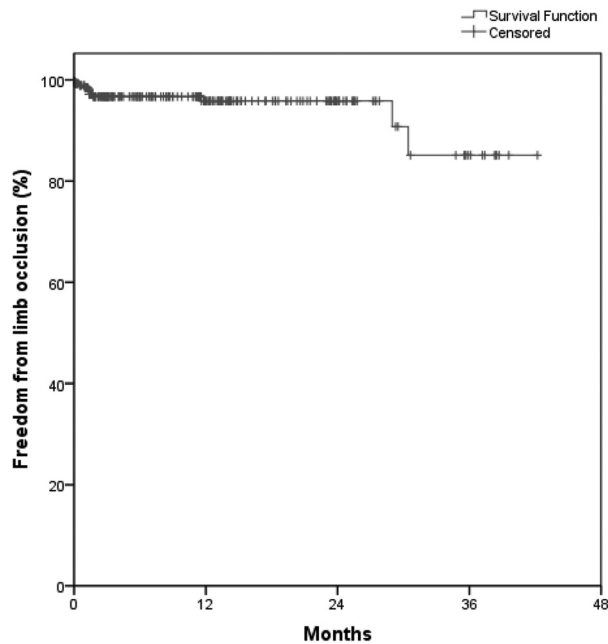
Figure 6. Kaplan-Meier analysis of freedom from target vessel stent distortion. Cum indicates cumulative; surv., survival.

(median total per center was 2), thus making this analysis closer to the real-world practice than any other published to date.

In the present series, f-EVAR was associated with a perioperative mortality rate of 4.1%, which is marginally higher than noted in other series.<sup>14</sup> In most contemporary reports of aortic surgery, single-center series generally report more favorable results than population-based or national samples.<sup>15</sup> In many cases, particularly with respect to thoracoabdominal aneurysms and a few centers of excellence, the discrepancy is striking, but, in the present series, the results are comparable, which suggests that fenestrated technology may be readily transferable to established specialized centers. There are several potential explanations for the higher mortality observed. It is possible that the patients included in this series are a higher-risk group than those in the other series. This cannot be verified because none of the other reports are risk adjusted, but there is precedent for the United Kingdom having a more comorbid patient cohort. It has been suggested that simpler f-EVAR configurations, such as 2 fenestrations or 2 fenestrations and a scallop, are associated with lower mortality compared with more complex configurations. Although a greater risk of death was observed with greater complexity of f-EVAR, this greater risk failed to reach statistical significance, probably because of sample size.

There are no randomized trial data that compare open and fenestrated approaches for juxtarenal aneurysms. The present study used a physiological scoring system to estimate the mortality from open repair in the cohort of patients treated with f-EVAR. The V-POSSUM system has been validated to





Time (months)	0	3	6	12	24	36	42
n at risk	309	196	161	125	49	13	1
Cum. Freedom (%)	99	97	97	96	96	85	85
Std.Err.(Cum.surv.)	0.01	0.01	0.01	0.01	0.01	0.07	0.07

**Figure 7.** Kaplan–Meier analysis of freedom from late limb occlusion. Cum indicates cumulative; surv., survival.

estimate perioperative mortality accurately with open vascular surgery.<sup>16,17</sup> From the calculated mortality risk with open surgery, a large proportion of f-EVAR patients belonged to a high-risk category. Comparing the observed 4.1% death rate following f-EVAR with the estimated 11% in the event of an open repair, the absolute mortality reduction attributable to f-EVAR can be tentatively estimated at 6.9%. This should be seen only as an approximate indication because of significant limitations to this methodology. The risk estimation model was validated for abdominal aortic aneurysm repair but not specific to juxtarenal aneurysm repair. The model was also designed to underestimate mortality when data are missing. We attempted to minimize this effect by including in V-POSSUM analysis only those patients with a minimum data set. This analysis, however, is hoped to guide current clinical practice to some extent and provide direction for prospective comparative studies with adequate power.

A significant finding in this series is the 5 patients whose procedure was complicated by spinal ischemia, a well-recognized complication with thoracoabdominal repairs but less well described in the fenestrated literature.<sup>18,19</sup> In 4 of 5 patients with spinal ischemia, the stent-graft extended to the celiac axis. The risk of spinal ischemia following f-EVAR appears tangible, and the different strategies currently applied in high-risk patients undergoing thoracic or thoracoabdominal aortic repair might be applicable to f-EVAR.<sup>20</sup> Further studies will clearly be required to define the high-risk subsets of patients undergoing f-EVAR, but the proximal extent of the endograft appears to be implicated in the current series.

The presence of modular junctions within the proximal seal zone creates additional potential for endoleaks within this area. Furthermore, balloon molding of the proximal seal zone, a highly effective maneuver to enhance proximal seal with a standard stent-graft is usually avoided because of the presence of target vessel stents. These factors may explain the type I endoleaks noted on completion. Every attempt was made to abolish a graft-related endoleak, and conservative management was adopted only when all efforts had failed. Maneuvers used to treat such endoleaks included balloon molding, insertion of Palmaz stent (Cordis), deployment of body extension, relining the modular junction, and reballoon or relining a target vessel stent. These maneuvers were performed both intraoperatively and as separate secondary interventions (Tables 5 and 7).

Target vessel patency is an important marker of success, and primary loss was noted in 0.6%. It is interesting to note that 3 patients of the 5 who had a primary loss of target vessel experienced a perioperative death. The relative significance of target vessel loss in causation of death was not established, and it may be that aortic morphology played some part. Although overall patency was good and catastrophic consequences of target vessel loss rare, a large proportion of intraoperative adjuvant maneuvers, early and late secondary interventions were required to achieve this. The majority of secondary interventions were endoluminal procedures, and none resulted in mortality. Kaplan–Meier analysis of these events revealed no reduction in their incidence with follow-up, suggesting that life-long surveillance may be required for these patients. In line with several other collaborative multicenter studies, this series also suffers from a drop in compliance with follow-up data, but standard error remained acceptable.

## Conclusions

A substantial proportion of patients undergoing f-EVAR in the United Kingdom appear to be in a high-risk category. This study has estimated the potential risk reduction associated with an endovascular approach and suggests that it may be substantial, certainly within experienced centers. The present study demonstrates good target vessel patency in the early postoperative phase, but also suggests that endograft-related complications and reinterventions continue in the long term. In the light of recent findings related to the long-term outcome of infrarenal EVAR, the present study suggests that defining the long-term outcome of f-EVAR should be a priority.

## Appendix

Collaborators are listed below. Disclosures and conflicts of interest are given in the disclosures section. G. Ambler, J.R. Boyle, C. Cousins, P.D. Hayes, T. Metha, T.C. See, K. Varty and A. Winterbottom (Addenbrooke's Hospital, Cambridge). D.J. Adam, A.W. Bradbury (Birmingham Heartlands Hospital, Birmingham). M.J. Clarke, R. Jackson, J.D. Rose, A. Sharif, V. Wealleans, R. Williams, L. Wilson, M.G. Wyatt (Freeman Hospital, Newcastle upon Tyne). I. Ahmed, R.E. Bell, T.W. Carrell, P. Gkoutzios, T. Sabharwal, R. Salter, M. Waltham (Guy's & St. Thomas' Hospital, London). C. Bicknell, P. Bourke, N. Cheshire, I. Franklin, A. James, M.P. Jenkins (Imperial College Hospitals, London). M.R. Tyrrell, C.J. Wilkins (King's College Hospital, London). M. Bown, E. Choke, M. McCarthy, R. Sayers, A. Tamberaja (Leicester Royal

Infirmery, Leicester). F. Farquharson, F. Serracino-Inglott (Manchester Royal Infirmary, Manchester). M. Davis, G. Hamilton (Royal Free Hospital, London). J.A. Brennan, R. Canavati, R.K. Fisher, R.G. McWilliams, J.B. Naik, S.R. Vallabhaneni (Royal Liverpool University Hospital, Liverpool). J. Hardman (Royal United Hospital, Bath). S. Black, R. Hinchliffe, P. Holt, I.M. Loftus, T. Loosemore, R. Morgan, M.M. Thompson (St. George's Hospital, London). O. Agu, C. Bishop, D. Boardley, J. Cross, J. Hague, P.L. Harris, K. Ivancev, J. Raja, T. Richards, D. Simring (University College London Hospital, London). A.C. Fisher, D. Smith (Globalstar on-line database IT support, University of Liverpool, Liverpool). G.P. Copeland (POSSUM advice, Warrington General Hospital, Warrington).

### Sources of Funding

This project was supported by The Vascular Surgery Research Fund (a registered charity established at the Royal Liverpool University Hospital) and an unrestricted grant to the British Society of Endovascular Therapy from Cook Medical.

### Disclosures

D.J. Adam reported being a preceptor for Cook Medical. Dr Farquharson declares being a proctor for Cook Medical and holding shares in Cardiatis. F. Serracino-Inglott is a proctor for Cook Medical and LeMaitre, receives grant income from Medtronic Inc, and is a consultant for Trivascular. Dr Vallabhaneni received conference travel expenses from Cook Medical and is a successful applicant for an unrestricted grant from Cook Medical. Dr Hardman has been a proctor for Cook Medical devices. Prof Ivancev has licensed patents to Cook Medical from whom he also receives royalties, research funds, and travel expenses. The other authors report no conflicts.

### References

- Greenhalgh RM, Brown LC, Powell JT, Thompson SG, Epstein D, Sculpher MJ. Endovascular versus open repair of abdominal aortic aneurysm. *N Engl J Med*. 2010;362:1863–1871.
- Greenhalgh RM, Brown LC, Powell JT, Thompson SG, Epstein D, Sculpher MJ. Endovascular versus open repair of abdominal aortic aneurysm. *N Engl J Med*. 2010;362:1863–1871.
- Greenberg RK, Lytle B. Endovascular repair of thoracoabdominal aneurysms. *Circulation*. 2008;117:2288–2296.
- Amiot S, Haulon S, Becquemin JP, Magnan PE, Lermusiaux P, Goueffic Y, Jean-Baptiste E, Cochenec F, Favre JP. Fenestrated endovascular grafting: the French multicentre experience. *Eur J Vasc Endovasc Surg*. 2010;39:537–544.
- Verhoeven EL, Vourliotakis G, Bos WT, Tielliu IF, Zeebregts CJ, Prins TR, Bracale UM, van den Dungen JJ. Fenestrated stent grafting for short-necked and juxtarenal abdominal aortic aneurysm: an 8-year single-centre experience. *Eur J Vasc Endovasc Surg*. 2010;39:529–536.
- McCulloch P, Altman DG, Campbell WB, Flum DR, Glasziou P, Marshall JC, Nicholl J, Aronson JK, Barkun JS, Blazeby JM, Boutron IC, Clavien PA, Cook JA, Ergina PL, Feldman LS, Madder GJ, Reeves BC, Seiler CM, Strasberg SM, Meakins JL, Ashby D, Black N, Bunker J, Burton M, Campbell M, Chalkidou K, Chalmers I, de Leval M, Deeks J, Grant A, Gray M, Greenhalgh R, Jenicek M, Kehoe S, Lilford R, Littlejohns P, Loke Y, Madhock R, McPherson K, Meakins J, Rothwell P, Summerskill B, Taggart D, Tekkis P, Thompson M, Treasure T, Trohler U, Vandenbroucke J. No surgical innovation without evaluation: the IDEAL recommendations. *Lancet*. 2009;374:1105–1112.
- Schanzer A, Greenberg RK, Hevelone N, Robinson WP, Eslami MH, Goldberg RJ, Messina L. Predictors of abdominal aortic aneurysm sac enlargement after endovascular repair. *Circulation*. 2011;123:2848–2855.
- Wyss TR, Brown LC, Powell JT, Greenhalgh RM. Rate and predictability of graft rupture after endovascular and open abdominal aortic aneurysm repair: data from the EVAR Trials. *Ann Surg*. 2010;252:805–812.
- Fillinger MF, Greenberg RK, McKinsey JF, Chaikof EL. Reporting standards for thoracic endovascular aortic repair (TEVAR). *J Vasc Surg*. 2010;52:1022–1033, 1033.e15.
- Browne TF, Hartley D, Purchas S, Rosenberg M, Van Schie G, Lawrence-Brown M. A fenestrated covered suprarenal aortic stent. *Eur J Vasc Endovasc Surg*. 1999;18:445–449.
- Moore R, Hinojosa CA, O'Neill S, Mastracci TM, Cina CS. Fenestrated endovascular grafts for juxtarenal aortic aneurysms: a step by step technical approach. *Catheter Cardiovasc Interv*. 2007;69:554–571.
- Rao Vallabhaneni S, Brennan J, Buth J, Harris P, Haulon S, Ivancev K, Katzen B, Laheij R, Lumsden A, McWilliams R, Nienaber C, Thompson M, Verhoeven E. Global collaborators on advanced stent-graft techniques for aneurysm repair (GLOBALSTAR) project. *J Endovasc Ther*. 2007;14:352–356.
- Chaikof EL, Blankensteijn JD, Harris PL, White GH, Zarins CK, Bernhard VM, Matsumura JS, May J, Veith FJ, Fillinger MF, Rutherford RB, Kent KC. Reporting standards for endovascular aortic aneurysm repair. *J Vasc Surg*. 2002;35:1048–1060.
- Greenberg R, Eagleton M, Mastracci T. Branched endografts for thoracoabdominal aneurysms. *J Thorac Cardiovasc Surg*. 2010;140:S171–S178.
- Blankensteijn JD, Lindenburg FP, Van der Graaf Y, Eikelboom BC. Influence of study design on reported mortality and morbidity rates after abdominal aortic aneurysm repair. *Br J Surg*. 1998;85:1624–1630.
- McIlroy BS, Copeland GP. An evaluation of the POSSUM surgical scoring system. *Br J Surg*. 1996;83:1483–1484.
- Tang TY, Walsh SR, Prytherch DR, Wijewardena C, Gaunt ME, Varty K, Boyle JR. POSSUM models in open abdominal aortic aneurysm surgery. *Eur J Vasc Endovasc Surg*. 2007;34:499–504.
- Eagleton MJ, Greenberg RK. Spinal and visceral ischemia after endovascular aortic repair. *J Cardiovasc Surg*. 2010;51:71–83.
- Drinkwater SL, Goebells A, Haydar A, Bourke P, Brown L, Hamady M, Gibbs RG. The incidence of spinal cord ischaemia following thoracic and thoracoabdominal aortic endovascular intervention. *Eur J Vasc Endovasc Surg*. 2010;40:729–735.
- Buth J, Harris PL, Hobo R, van Eps R, Cuypers P, Duijml L, Tielbeek X. Neurologic complications associated with endovascular repair of thoracic aortic pathology: incidence and risk factors. a study from the European Collaborators on Stent/Graft Techniques for Aortic Aneurysm Repair (EUROSTAR) registry. *J Vasc Surg* 2007;46:1103–1110; discussion 1110–1111.

### CLINICAL PERSPECTIVE

The technique of fenestrated endovascular repair (f-EVAR) of aortic aneurysm has been developed for use in juxtarenal and pararenal aneurysms that do not have an adequate aneurysm neck to allow a standard endovascular repair. Existing literature is a source of optimism, but it has been predominantly from expert operators who have been involved in the development of complex endograft design. It remained unknown if their results could be reproduced in the wider clinical practice. This is an important question, because the use of this technique is expanding rapidly and outside the pioneering centers. The British Society for Endovascular Therapy launched this study with the purpose of establishing nationwide results of f-EVAR without selection or reporting biases. Every center in the United Kingdom with an established f-EVAR service collaborated for this study with the aim of including every f-EVAR done during the study period. Data were collected through the GLOBALSTAR on-line registry. This analysis of early results confirm that, in the United Kingdom, national results of f-EVAR are comparable to those from single-center series. This finding justifies the continued use and evaluation of the f-EVAR by means of a prospective multicenter study.