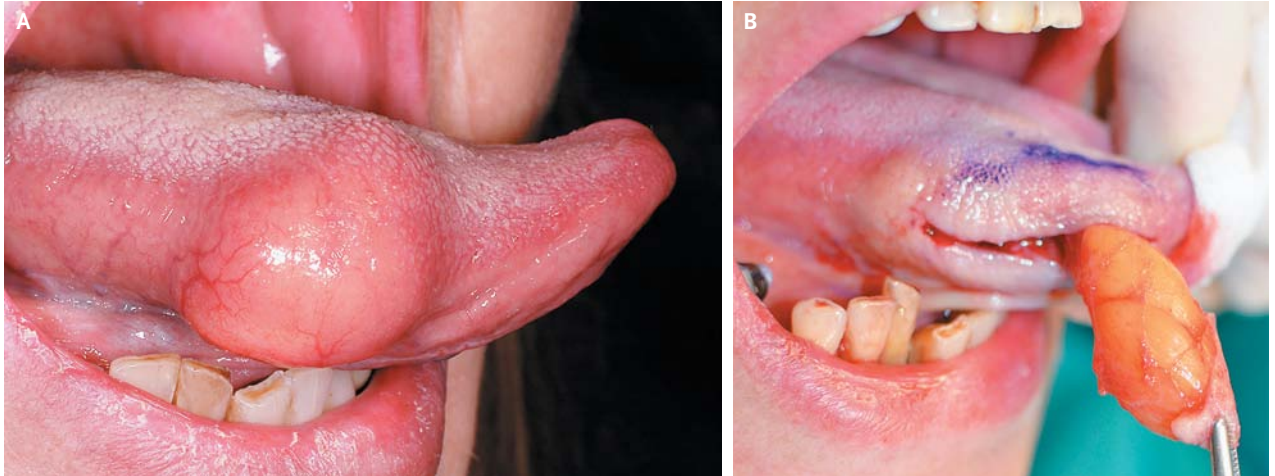


IMAGES IN CLINICAL MEDICINE

Lipoma of the Tongue



A 45-YEAR-OLD WOMAN PRESENTED WITH A PAINLESS SUBMUCOSAL swelling on the right side of her tongue. The lesion had been growing insidiously for 5 years. Examination of the tongue revealed a nontender, soft, spherical mass on the right side of the tongue, measuring 2 cm in diameter, that was suggestive of a lipoma (Panel A). The tumor was surgically removed (Panel B), and histopathological examination confirmed the diagnosis of a lipoma. Healing was uneventful, and the patient showed no signs of recurrence at the end of the 24-month follow-up period. Lipoma is one of the most common benign neoplasms. In the mouth, the most frequent sites are the buccal mucosa and the tongue. Dermoid and epidermoid cysts, schwannoma, and lymphoepithelial cysts should be considered in the differential diagnosis.

DOI: 10.1056/NEJMicm1204020

Copyright © 2012 Massachusetts Medical Society.

Paolo Boffano, M.D.
Cesare Gallezio, M.D., D.D.S.

University of Turin
Turin, Italy
paolo.boffano@gmail.com