

# Usefulness of Transesophageal Bronchoscopic Ultrasound-guided Fine-Needle Aspiration in the Pathologic and Molecular Diagnosis of Lung Cancer Lesions Adjacent to the Esophagus

Tomoyuki Araya, MD,\* Yoshiki Demura, MD, PhD,\* Kazuo Kasahara, MD, PhD,†  
Hiroki Matsuoka, MD,\* Kenta Yamamura, MD,\* Masaru Nishitsuji, MD, PhD,\*  
and Koichi Nishi, MD, PhD\*

**Background:** The discovery of driver oncogenes has increased the need to obtain a sufficient amount of tissue specimens for lung cancer diagnosis. Although endoscopic ultrasound (with bronchoscope)-guided fine-needle aspiration (EUS-B-FNA) is reportedly a feasible and well-tolerated modality, additional advantages of EUS-B-FNA are yet to be thoroughly investigated. The purpose of this study was to evaluate the ability of EUS-B-FNA to obtain sufficient tissue specimens for pathologic and molecular diagnoses of lung cancer.

**Methods:** Among lung cancer patients who were diagnosed between December 2010 and December 2012 in our institute, patients who underwent EUS-B-FNA to diagnose lung cancer were enrolled (n = 26). EUS-B-FNA was performed when bronchoscopic diagnosis was impossible or difficult to obtain sufficient samples. Epidermal growth factor receptor (*EGFR*) mutations and echinoderm microtubule-associated protein-like 4 and the anaplastic lymphoma kinase (*EML4-ALK*) fusion gene were evaluated using EUS-B-FNA samples of non-small cell lung cancer.

**Results:** EUS-B-FNA was performed on 28 lesions in 26 patients. Among the target lesions, 23 were mediastinal lymph nodes including nodal stations 2L, 4L, 7, 8, and 10L. The remaining 5 were intrapulmonary lesions. EUS-B-FNAs were completed without complications in all the patients. The diagnostic yield of EUS-B-FNA in diagnosing lung cancer was 100% (26/26). Additional diagnostic gain of EUS-B-FNA was 69.2% (18/26) as compared to bronchoscopy alone. *EGFR* mutations and *EML4-ALK* fusion gene could be evaluated in all

patients with non-small cell lung cancer (n = 20) using EUS-B-FNA samples. One case with *EGFR* mutation and 1 case with *ALK* fusion gene were diagnosed. Six non-small cell carcinomas were also diagnosed by bronchoscopy, but all bronchoscopic samples were insufficient to evaluate mutation analyses.

**Conclusions:** EUS-B-FNA is a practical and feasible method to obtain abundant tumorous tissue samples for pathologic diagnosis and molecular analysis, particularly when the target lesions are inaccessible by other modalities because of their locations or because of the patient's poor physical condition.

**Key Words:** transesophageal bronchoscopic ultrasound-guided fine-needle aspiration, tissue samples, molecular analysis, minimal invasiveness, poor physical condition

(*J Bronchol Intervent Pulmonol* 2013;20:121–126)

Lung cancer is one of the most common neoplasms worldwide and through the development of molecular biology techniques, targeted therapy has become mainstream in the treatment of non-small cell lung cancer (NSCLC).<sup>1</sup> In the recent years, the discovery of driver oncogenes, such as mutations in epidermal growth factor receptor (*EGFR*), a fusion gene comprising portions of the echinoderm microtubule-associated protein-like 4 gene, and the anaplastic lymphoma kinase gene (*EML4-ALK*),<sup>2–4</sup> has increased the need to obtain a sufficient amount of tissue from cancerous lesions for lung cancer diagnosis. In addition, the development of the endobronchial ultrasound (EBUS) bronchoscope has dramatically enhanced the diagnostic ability of bronchoscopy. Previously, mediastinoscopy or thoracoscopic surgery was used to obtain tissue samples from mediastinal lesions adjacent to the esophagus, but not large airways. Mediastinal staging with needle aspiration through the

Received for publication January 24, 2013; accepted March 11, 2013.  
From the \*Department of Respiratory Medicine, Ishikawa Prefectural Central Hospital; and †Department of Respiratory Medicine, Cellular Transplantation Biology, Kanazawa University Graduate School of Medical Science, Kanazawa, Japan.

Disclosure: There is no conflict of interest or other disclosures.  
Reprints: Yoshiki Demura, MD, PhD, Department of Respiratory Medicine, Ishikawa Prefectural Central Hospital, 2-1 Kuratsuki-Higashi, Kanazawa 920-8530, Japan (e-mail: bzh42738@biglobe.ne.jp).

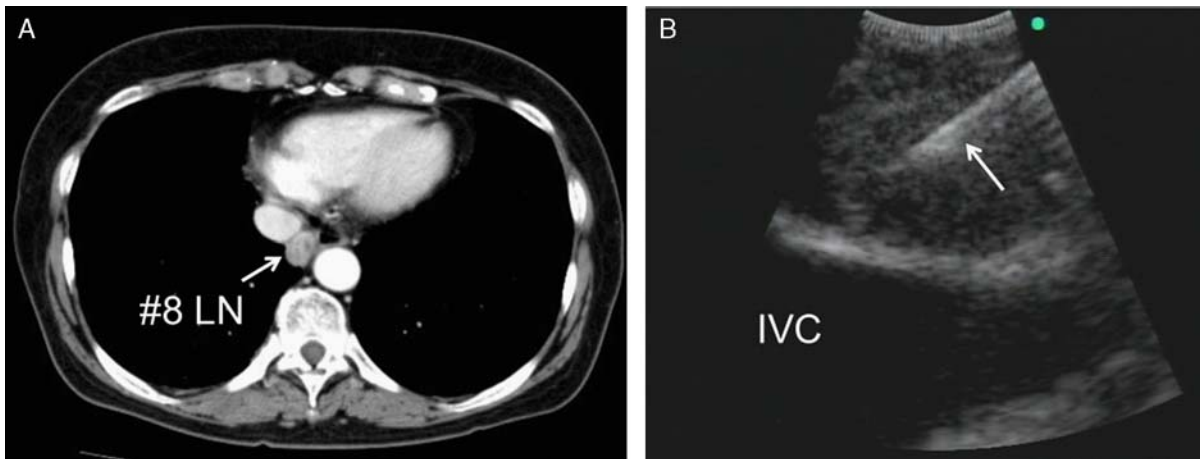
Copyright © 2013 by Lippincott Williams & Wilkins

esophagus [transesophageal endoscopic ultrasound-guided fine-needle aspiration (EUS-FNA)] using an EBUS bronchoscope (EUS-B-FNA) is feasible in cases with complicated lesions evaluated by conventional transbronchial approach, such as endobronchial ultrasound-guided transbronchial needle aspiration (EBUS-TBNA).<sup>5,6</sup> Furthermore, in cases with severe chronic obstructive pulmonary disease or chronic respiratory failure, bronchoscopy itself may cause serious complications. Reportedly, EUS-B-FNA caused less discomfort to patients compared with EUS-FNA using a dedicated endoscope.<sup>7-9</sup> Nonetheless, EUS-B-FNA is considered a feasible and well-tolerated modality, although all additional advantages of EUS-B-FNA have not yet been comprehensively investigated. In practice, the acquisition of appropriate tissue samples for molecular analyses is often challenging; however, information obtained from such specimens is essential for the selection of appropriately targeted cancer therapies. Recently, Sakairi et al<sup>10</sup> demonstrated the utility of EBUS-TBNA samples for detection of *EGFR* mutations or *EML4-ALK* fusion gene; however, some lesions were inaccessible by EBUS-TBNA because of their complicated locations or due to poor tolerance in patients with respiratory comorbidities.<sup>9</sup> In the present study, we retrospectively analyzed 26 cases of lung cancer diagnosed by EUS-B-FNA to evaluate its ability in obtaining tumorous tissue samples. This study also clarified whether tissue samples obtained by EUS-B-FNA can be used to assess the presence of *EGFR* activating mutations and *EML4-ALK* fusion gene.

#### PATIENTS AND METHODS

From December 2010 to December 2012, 604 patients underwent bronchoscopy in our institution for the diagnosis of abnormal shadows noted on their chest x-ray or computed tomography films. Of the 604 patients, 32 underwent EUS-B-FNA for suspected lung cancer. Of the 279 patients finally diagnosed with lung cancer, 26 patients who underwent EUS-B-FNA were enrolled in this study. The remaining 6 patients who underwent EUS-B-FNA were excluded from this study because of a final diagnosis other than lung cancer. Of the remaining 6 patients, a final diagnosis of sarcoidosis was made in 3, non-Hodgkin lymphoma in 2, and inflammatory lymphadenopathy in 1. The diagnostic standard for a malignant result was pathologic confirmation of malignancy by

any tissue sampling method (bronchoscopic modalities including EBUS-TBNA, EUS-B-FNA, or surgical biopsy). This retrospective study was approved by our institutional review boards and all procedures were performed by the authors. All patients provided written informed consent for EUS-B-FNA and were selected on the bronchoscopist's judgment based on the following conditions: (i) insufficient amount of tissue was obtained by transbronchial samplings before EUS-B-FNA; (ii) the lesions adjacent to esophagus were accessible only by EUS-FNA; and (iii) the patient's condition made it impossible or difficult to perform bronchoscopy. EUS-B-FNA was performed following a transbronchial approach, such as EBUS-TBNA or transbronchial lung biopsy (TBLB), under local anesthesia with conscious sedation by administration of midazolam (2 mg) and pentazocine (15 mg). When bronchoscopy was performed, it was applied before EUS-B-FNA in a single session by the same bronchoscopist. For EUS-B-FNA, a flexible EBUS endoscope (BF-UC260F-OL8; Olympus Corporation, Tokyo, Japan) was inserted and advanced through the esophagus with the patient in the supine position while examining the structure and blood vessels around the esophagus by ultrasound with Doppler flow imaging. Continuous ultrasound imaging was employed to assess appropriate location. The lesions were punctured through the esophagus with a 22-gauge EBUS needle (NA-201SX-4022; Olympus Corporation) with real-time ultrasonographic guidance, and the stylet was then removed. Suction was applied with a syringe by moving the needle back and forth inside the lesions, as previously reported.<sup>5,6,9</sup> Rapid onsite cytologic evaluations were not used in this study. The procedures were terminated after sufficient amount of tissue was obtained according to the bronchoscopist's decision. Finally, the needle was retrieved and the internal stylet was used to push out the histologic core, which was then fixed with formalin and used for pathologic diagnosis and molecular analyses as follows. For molecular analyses, the *EGFR* mutation status in EUS-B-FNA-derived samples was evaluated using the polymerase chain reaction-invaser assay and the presence of *EML4-ALK* fusion gene was evaluated by fluorescent in situ hybridization or immunohistochemical staining of the EUS-B-FNA samples. A representative case diagnosed only by EUS-B-FNA is shown in Figure 1.



**FIGURE 1.** A representative case diagnosed only by endoscopic ultrasound (with bronchoscope)-guided fine-needle aspiration. A, Thoracic computed tomography revealed a metastatic #8 lymph node (LN), 11 mm in diameter, located between the descending aorta and inferior vena cava (IVC) (arrow). B, Bronchoscopic ultrasound image showing a needle (arrow) penetrating a tumor adjacent to the IVC. *▲*

**RESULTS**

EUS-B-FNA was performed on 28 lesions in 26 patients. The clinical characteristics of all 26 patients are listed in Table 1. Among the target

**TABLE 1.** Clinical Characteristics of the Patients

Clinical Characteristics	n = 26
Mean age (range), y	66 (58-85)
Sex	
Male	22
Female	4
ECOG performance status	
0	1
1	10
2	11
3	4
Histologic type	
Adenocarcinoma	8
Squamous cell carcinoma	11
Small cell carcinoma	6
NOS	1
Stage	
IIIA	5
IIIB	3
IV	18
Punctured lesions by EUS-B-FNA (n = 28) n (%)	
#2L	1 (3.6)
#4L	8 (28.6)
#7	10 (35.7)
#8	3 (10.7)
#10L	1 (3.6)
Intrapulmonary lesion	5 (17.8)

ECOG indicates eastern cooperative oncology group; EUS-B-FNA, endoscopic ultrasound (with bronchoscope)-guided fine-needle aspiration; NOS, not otherwise specified.

lesions, 23 were mediastinal lymph nodes including nodal stations 2L, 4L, 7, 8, and 10L, and the remaining 5 were intrapulmonary lesions (Table 1). The mean diameter of the punctured lesions was 28.1 mm (range, 11 to 83 mm). Each target lesion was punctured an average of 2.6 times. The mean procedure time for EUS-B-FNA was 16 minutes and no complication occurred in any patient. No procedure had to be terminated early as a result of patient intolerance. Although, routine white light bronchoscopy and EBUS-TBNA before EUS-B-FNA was attempted in all patients, there were various reasons to avoid the transbronchial approach and select EUS-B-FNA, of which the majority were because of decreased respiratory function (26.9%) and poor performance status (19.2%) for reasons other than respiratory dysfunction (Table 2).

EUS-B-FNA was performed either independently or with other procedures, such as EBUS-TBNA and/or TBLB (Table 3). EUS-B-FNA was independently performed in 14 patients (53.8%) and in conjunction with EBUS-TBNA during the same session in 7 (26.9%). Of the remaining patients, 2 (7.8%) were examined by a combination of EUS-B-FNA and TBLB, and 3 (11.5%) by a combination of EUS-B-FNA plus airway observation. Histologic and cytologic diagnoses of lung cancer were established in 26 patients (NSCLC n = 20, small cell lung cancer n = 6). The diagnostic yield of EUS-B-FNA was 100%. As shown in Table 3, of the 26 patients diagnosed by EUS-B-FNA, 18 (69.2%)

**TABLE 2.** Key Reasons for EUS-B-FNA

Key Reasons for EUS-B-FNA (n = 26)	n (%)
Poor performance status	5 (19.2)
Poor respiratory condition	6 (26.9)
Target lesions beyond the reach of EBUS-TBNA	4 (15.4)
Difficult to obtain a sufficient samples by EBUS-TBNA	7 (26.9)
Poor performance status + Target lesion beyond the reach of EBUS-TBNA	2 (7.7)
Poor respiratory condition + Target lesions beyond the reach of EBUS-TBNA	1 (3.9)

EBUS-TBNA indicates endobronchial ultrasound-guided transbronchial needle aspiration; EUS-B-FNA, endoscopic ultrasound (with bronchoscope)-guided fine-needle aspiration.

were diagnosed only by EUS-B-FNA (additional gain) and 8 (6 NSCLC cases and 2 small cell lung cancer) were diagnosed by both the transbronchial approach and EUS-B-FNA. However, the amount of tumor tissue obtained from 6 NSCLC patients by the transbronchial approach was insufficient for molecular analyses. In addition, the *EGFR* mutation status of all 20 NSCLC patients was successfully evaluated in EUS-B-FNA-derived samples using the polymerase chain reaction-invader assay. As shown in Table 4, an *EGFR* mutation was detected in 1 case (3.9%), which was a short in-frame deletion in exon 19 (E746-A750 del type 1). This patient underwent gefitinib monotherapy as first-line treatment. Two weeks after gefitinib administration, a partial response was indicated by marked tumor shrinkage. Furthermore, the presence of *EML4-ALK* fusion gene was successfully evaluated by fluorescent in situ hybridization or immunohistochemical staining using EUS-B-FNA samples from all 20 NSCLC patients (Table 4). One of the 20 NSCLC patients was determined to be *ALK*-positive and was subsequently treated with crizotinib (500 mg/d) as a second-line treatment, which is an orally administered small-molecule inhibitor of *ALK*

**TABLE 4.** Molecular Analyses of EUS-B-FNA Samples Obtained From NSCLC Patients

Driver Oncogenes	n = 20
<i>EGFR</i> mutational status in NSCLC (n = 20)	
Wild-type	19
Mutant	1
Unknown	0
Detection of <i>EML4-ALK</i> fusion gene in NSCLC (n = 20)	
Negative	19 (FISH n = 10, IHC n = 9)
Positive	1 (FISH n = 1)
Unknown	0

*EGFR* indicates epidermal growth factor receptor; *EML4-ALK*, the echinoderm microtubule-associated protein-like 4 and the anaplastic lymphoma kinase; EUS-B-FNA, endoscopic ultrasound (with bronchoscope)-guided fine-needle aspiration; FISH, fluorescent in situ hybridization; IHC, immunohistochemical staining; NSCLC, non-small cell lung cancer.

tyrosine kinase approved for advanced *ALK*-positive NSCLC in Japan. Four weeks after crizotinib administration, a partial response was indicated by marked tumor shrinkage and symptom relief. Furthermore, among 15 patients with poor a physical condition and diagnosis of lung cancer, 10 (66.7%) were sufficiently fit to receive chemotherapy or radiotherapy.

## DISCUSSION

The present study is the first to report the utility of EUS-B-FNA samples for the detection of *EGFR* mutations and *EML4-ALK* fusion gene. We also confirmed that EUS-B-FNA was a feasible and well-tolerated procedure in patients with cancerous lesions adjacent to the esophagus, but not large airways, even though all patients were in poor physical condition. We were able to easily perform EUS-B-FNA because the esophageal wall was soft and the cartilage was absent and the patients experienced a reduction in respiratory status and coughing. As previously reported in EBUS-TBNA,<sup>11</sup> a major factor hindering diagnosis is the presence of tracheal or bronchial cartilage, which impedes

**TABLE 3.** Diagnostic Yield of Each Modality

Modality	n	Diagnostic Yield Without EUS-B-FNA	Diagnostic Yield by EUS-B-FNA	
EUS-B-FNA independent	14	0/14 (0%)	14/14 (100%)	
EUS-B-FNA + airway observation	3	0/3 (0%)	3/3 (100%)	Additional gain
EUS-B-FNA + TBLB	2	1/2 (50%)	2/2 (100%)	18/26 (69.2%)
EUS-B-FNA + EBUS-TBNA	5	5/5 (100%)	5/5 (100%)	
EUS-B-FNA + EBUS-TBNA + TBLB	2	2/2 (100%)	2/2 (100%)	

EBUS-TBNA indicates endobronchial ultrasound-guided transbronchial needle aspiration; EUS-B-FNA, endoscopic ultrasound (with bronchoscope)-guided fine-needle aspiration; TBLB, transbronchial lung biopsy.

puncturing the tissue. The softness of the esophageal wall and its absence of cartilage make it easily penetrable to obtain a substantial amount of tissue without puncturing cartilage or bending needles. Hence, we were able to repeatedly acquire samples, usually up to 4 times, to obtain sufficient tissue amounts.

The biopsy samples obtained by EUS-B-FNA were successfully subjected to histologic and cytologic evaluations, as previously reported for EBUS-TBNA.<sup>10</sup> Nonsurgical modalities to obtain tumor specimens are particularly critical in lung cancer because many patients were at an advanced stage of disease at the time of first presentation and are therefore not eligible for radical surgery. In addition to the histologic diagnosis, EUS-B-FNA enabled molecular analyses of the biopsy samples. In this study, both the presence of *EML4-ALK* fusion gene as well as *EGFR* mutations were successfully evaluated in all NSCLC patients using histologic samples obtained by EUS-B-FNA. Furthermore, we demonstrated that *EGFR* mutations or *EML4-ALK* fusion gene detected using EUS-B-FNA tissue samples could be useful to predict the response to gefitinib or crizotinib.

Conversely, more than one half of the patients in this study were in poor physical condition. In general, bronchoscopic sampling, such as EBUS-TBNA and/or TBLB, is inappropriate if the patient's respiratory status is poor; therefore, such patients cannot receive active treatment. Nevertheless, all 15 patients with poor conditions in this study were diagnosed with lung cancer and 10 (66.7%) were able to receive chemotherapy or radiotherapy, which was possibly attributed to early diagnosis using an easier EUS-B-FNA method. The use of EUS-B-FNA may be more comfortable than a dedicated EUS-FNA endoscope. Reportedly, upper gastrointestinal endoscopy using a small diameter endoscope involved less discomfort.<sup>12</sup> The flexible EBUS endoscope used in this study was 6.9 mm in diameter, whereas a dedicated EUS-FNA endoscope commonly used in Japan is 14.6 mm in diameter. As a result, we were able to perform EUS-B-FNA less invasively with minimal sedation and respiratory care. The minimal invasiveness of EUS-B-FNA allows an easy combination of EUS-B-FNA with conventional bronchoscopic modalities, as concluded in this study, and enables the operator to obtain substantial tissue samples.

Classic EUS-FNA using a dedicated endoscope is reportedly a useful and reliable initial

diagnostic modality for establishing lung cancer diagnosis.<sup>13–15</sup> In the present study, the diagnostic yield of EUS-B-FNA was comparable to that of EBUS-TBNA previously reported.<sup>16</sup> Furthermore, an additional gain of diagnostic yield by EUS-B-FNA in this study was 69.2% (18/26 patients). Increased quantities of EUS-B-FNA samples required for molecular analyses were retrieved from all NSCLC patients. Reportedly, EUS-FNA and EBUS-TBNA are complementary and it is necessary to combine these methods for lung cancer diagnosis because some accessible regions slightly differ.<sup>17–19</sup> However, Oki et al<sup>7</sup> reported that the combination of these procedures, which require separate equipment and/or examiners, is much more complex than either procedure by itself. To simplify this promising approach, the use of an EBUS bronchoscope in EUS-FNA is reasonable. EUS-B-FNA is a feasible method to obtain sufficient amounts of tumorous tissue, even if the target lesions are inaccessible by other modalities because of their locations or due to the patient's poor physical condition; however, accessible lesions using this method in chest diseases are limited to those adjacent to the esophagus compared with those using EBUS-TBNA. Therefore, we recommend the use of EUS-B-FNA as an adjunct or alternative to EBUS-TBNA.

Limitations to the present study included a relatively small number of patients and its retrospective nature at a single medical center. Further, the diagnostic yield of EUS-B-FNA may vary by several factors, including the experience of the endoscopists, pathologists, and laboratory technicians. Nonetheless, we believe that future studies are necessary to validate additional advantages of EUS-B-FNA.

## CONCLUSIONS

EUS-B-FNA is a practical and feasible method to obtain sufficient tumorous tissue samples even if the target lesions are inaccessible by other modalities because of their locations or due to the patient's poor physical condition. Tissue samples obtained by EUS-B-FNA can be subjected to multimodal analysis of *EGFR* mutations and *EML4-ALK* fusion gene in NSCLC.

## REFERENCES

1. Gridelli C, De Marinis F, Di Maio M, et al. Gefitinib as first-line treatment for patients with advanced non-small-cell lung cancer with activating epidermal growth factor receptor mutation: implications for clinical practice and open issues. *Lung Cancer*. 2011; 72:3–8.

2. Lynch TJ, Bell DW, Sordella R, et al. Activating mutations in the epidermal growth factor receptor underlying responsiveness of non-small-cell lung cancer to gefitinib. *N Engl J Med*. 2004;350:2129–2139.
3. Paez JG, Jänne PA, Lee JC, et al. *EGFR* mutations in lung cancer: correlation with clinical response to gefitinib therapy. *Science*. 2004;304:1497–1500.
4. Soda M, Choi YL, Enomoto M, et al. Identification of the transforming *EML4-ALK* fusion gene in non-small-cell lung cancer. *Nature*. 2007;448:561–566.
5. Herth FJ, Krasnik M, Kahn N, et al. Combined endoscopic-endobronchial ultrasound-guided fine-needle aspiration of mediastinal lymph nodes through a single bronchoscope in 150 patients with suspected lung cancer. *Chest*. 2010;138:790–794.
6. Hwangbo B, Lee GK, Lee HS, et al. Transbronchial and transesophageal fine-needle aspiration using an ultrasound bronchoscope in mediastinal staging of potentially operable lung cancer. *Chest*. 2010;138:795–802.
7. Oki M, Saka H, Kitagawa C, et al. Bronchoscopic transesophageal ultrasound-guided needle aspiration: an alternative to the conventional transesophageal ultrasound-guided needle aspiration technique. *J Thorac Cardiovasc Surg*. 2010;139:1659–1661.
8. Oki M, Saka H, Kitagawa C. Transesophageal bronchoscopic ultrasound-guided fine-needle aspiration for diagnosis of peripheral lung cancer. *Ann Thorac Surg*. 2011;91:1613–1616.
9. Hwangbo B, Lee HS, Lee GK, et al. Transoesophageal needle aspiration using a convex probe ultrasonic bronchoscope. *Respirology*. 2009;14:843–849.
10. Sakairi Y, Nakajima T, Yasufuku K, et al. *EML4-ALK* fusion gene assessment using metastatic lymph node samples obtained by endobronchial ultrasound-guided transbronchial needle aspiration. *Clin Cancer Res*. 2010;16:4938–4945.
11. Inoue T, Kurimoto N, Furuya N, et al. New technique for endobronchial ultrasound-guided transbronchial needle aspiration to improve diagnostic yield. *J Bronchol Interv Pulmonol*. 2013;20:28–32.
12. Mulcahy HE, Riches A, Kiely M, et al. A prospective controlled trial of an ultrathin versus a conventional endoscope in unsedated upper gastrointestinal endoscopy. *Endoscopy*. 2001;33:311–316.
13. Varadarajulu S, Hoffman BJ, Hawes RH, et al. EUS-guided FNA of lung masses adjacent to or abutting the esophagus after unrevealing CT-guided biopsy or bronchoscopy. *Gastrointest Endosc*. 2004;60:293–297.
14. Sawhney MS, Kratzke RA, Lederle FA, et al. EUS-guided FNA for the diagnosis of advanced lung cancer. *Gastrointest Endosc*. 2006;63:959–965.
15. Singh P, Camazine B, Jadhav Y, et al. Endoscopic ultrasound as a first test for diagnosis and staging of lung cancer: a prospective study. *Am J Respir Crit Care Med*. 2007;175:345–354.
16. Tournoy KG, Rintoul RC, van Meerbeeck JP, et al. EBUS-TBNA for the diagnosis of central parenchymal lung lesions not visible at routine bronchoscopy. *Lung Cancer*. 2009;63:45–49.
17. Wallace MB, Pascual JM, Raimondo M, et al. Minimally invasive endoscopic staging of suspected lung cancer. *JAMA*. 2008;299:540–546.
18. Rintoul RC, Skwarski KM, Murchison JT, et al. Endobronchial and endoscopic ultrasound-guided real-time fine-needle aspiration for mediastinal staging. *Eur Respir J*. 2005;25:416–421.
19. Vilmann P, Krasnik M, Larsen SS, et al. Transesophageal endoscopic ultrasound-guided fine-needle aspiration (EUS-FNA) and endobronchial ultrasound-guided transbronchial needle aspiration (EBUS-TBNA) biopsy: a combined approach in the evaluation of mediastinal lesions. *Endoscopy*. 2005;37:833–839.