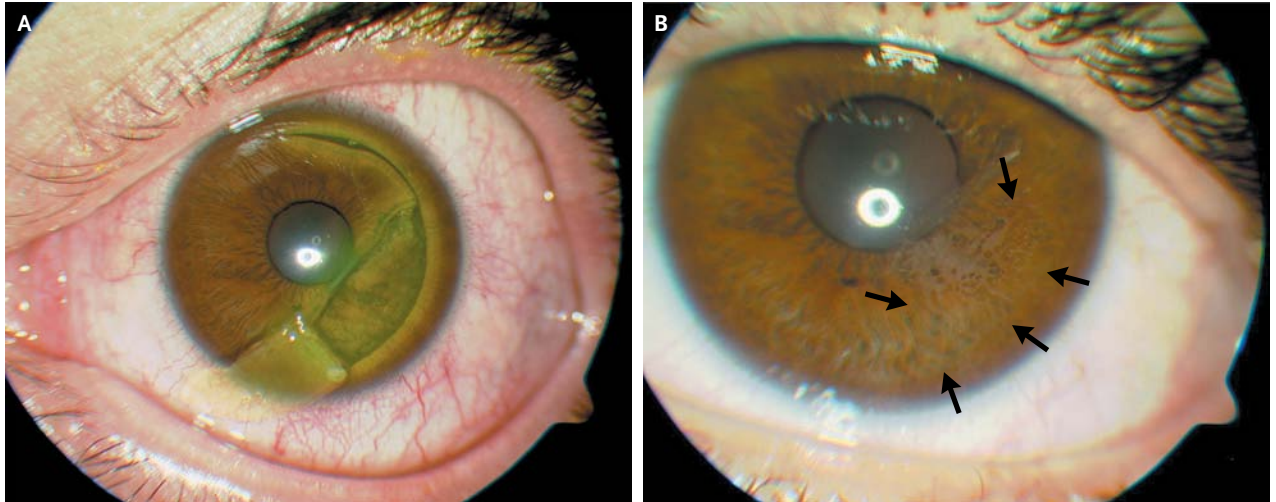


IMAGES IN CLINICAL MEDICINE

Corneal-Flap Dehiscence after Screwdriver Trauma



A 29-YEAR-OLD MAN PRESENTED WITH BLURRED VISION, PHOTOPHOBIA, and pain after trauma to his left eye caused by a screwdriver. He had a history of moderate myopia (visual acuity, 20/25) and had undergone uneventful bilateral laser-assisted in situ keratomileusis (LASIK) 10 years previously. On examination, he had a 180-degree traumatic corneal flap dislocation with an inverted tear in the temporal cornea (Panel A, fluorescein dye). After repositioning of the flap, a disposable contact lens, used as a therapeutic bandage, was placed on the cornea. Topical antibiotics and glucocorticoids were administered. One month postoperatively, his previous visual acuity had recovered and the dislodged flap showed an epithelial ingrowth (Panel B, arrows), which did not require removal. LASIK is a commonly performed type of refractive surgery. Postoperative flap dislocations occur in approximately 1% of patients, usually within the first 24 hours after surgery. Late flap dehiscence due to trauma is a rare complication and suggests that the interface between the flap and the stromal bed is a potential zone of weakness for many years after the procedure.

DOI: 10.1056/NEJMicm1204137

Copyright © 2013 Massachusetts Medical Society.

Nelson A. Rodríguez, M.D.

Hospital of Navarra
Pamplona, Spain

Francisco J. Ascaso, M.D., Ph.D.

Lozano Blesa University Clinic Hospital
Zaragoza, Spain
jascaso@gmail.com