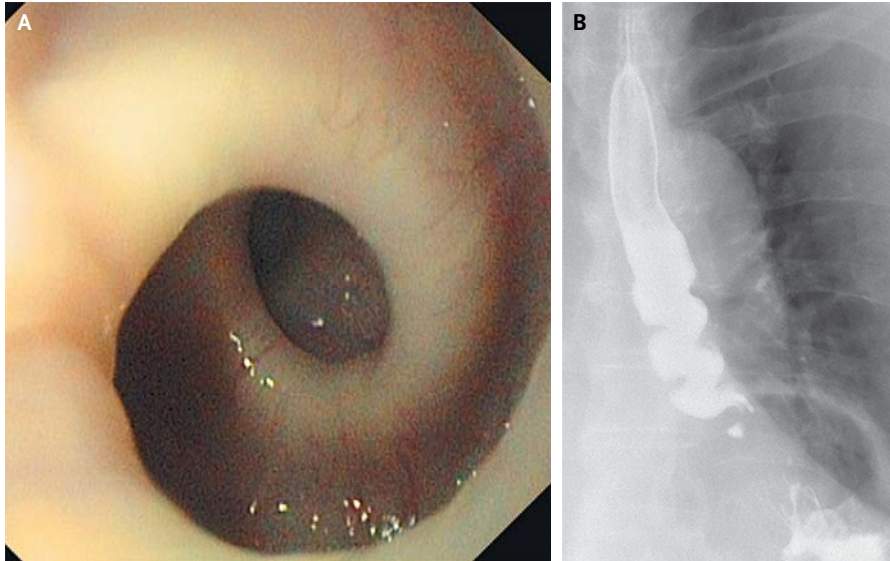


## IMAGES IN CLINICAL MEDICINE

## Nutcracker Esophagus



**A**N 87-YEAR-OLD WOMAN WITH SEVERE RETROSTERNAL PAIN AND INTERMITTENT dysphagia was referred to the clinic for further evaluation. She described paroxysms of crampy pain almost exclusively during the intake of solid foods. In the past several months, she noted a weight loss of 5 kg. Endoscopy revealed a pronounced helical configuration of the esophageal lumen (Panel A and Video). Strong esophageal contractions occurred such that any advancement or withdrawal of the endoscope was hindered for several seconds. A barium swallow revealed a corkscrew appearance (Panel B). High-resolution manometry of the esophagus showed high-amplitude pressure waves, indicating a hypertensive peristaltic disorder of the esophagus. Because this patient had normal relaxation of the esophagogastric junction, no premature contractions, and a mean distal contractile integral (a calculation of the amplitude, duration, and span of the esophageal contraction) greater than 5000 mm Hg·sec·cm, this motility disorder can be described as nutcracker esophagus. After a trial of high-dose proton-pump inhibitors led to no clinical improvement, we initiated treatment with long-acting diltiazem, which had only a limited clinical benefit and had to be stopped because of severe ankle edema.

Luc Biedermann, M.D.  
Oliver Götze, M.D.

University Hospital Zurich  
Zurich, Switzerland  
luc.biedermann@usz.ch

DOI: 10.1056/NEJMicm1210209

Copyright © 2013 Massachusetts Medical Society.