

## CASE RECORDS of the MASSACHUSETTS GENERAL HOSPITAL

Founded by Richard C. Cabot

Nancy Lee Harris, M.D., *Editor*  
 Jo-Anne O. Shepard, M.D., *Associate Editor*  
 Sally H. Ebeling, *Assistant Editor*

Eric S. Rosenberg, M.D., *Editor*  
 Alice M. Cort, M.D., *Associate Editor*  
 Emily K. McDonald, *Assistant Editor*



## Case 23-2013: A 54-Year-Old Woman with Abdominal Pain, Vomiting, and Confusion

Kamyar Kalantar-Zadeh, M.D., M.P.H., Ph.D., Raul N. Uppot, M.D.,  
 and Kent B. Lewandrowski, M.D.

### PRESENTATION OF CASE

From the Department of Medicine, University of California, Irvine, Orange (K.K.-Z.); and the Departments of Radiology (R.N.U.) and Pathology (K.B.L.), Massachusetts General Hospital, and the Departments of Radiology (R.N.U.) and Pathology (K.B.L.), Harvard Medical School — both in Boston.

*N Engl J Med* 2013;369:374-82.  
 DOI: 10.1056/NEJMcpc1208154  
 Copyright © 2013 Massachusetts Medical Society.

*Dr. Sara R. Schoenfeld (Medicine):* A 54-year-old woman was admitted to this hospital because of abdominal pain, vomiting, and confusion.

The patient was in her usual health until approximately 3 days before admission, when she reportedly began to feel unwell, with weakness, chills, and skin that was abnormally warm to the touch. She self-administered aspirin, without improvement. During the next 2 days, her oral intake decreased. Approximately 22 hours before presentation, vomiting occurred. Nine hours before presentation, she began to travel home to Italy from the eastern United States. During the next 2 hours, increasing abdominal pain occurred, associated with vomiting and shortness of breath, and she took additional aspirin for pain. Approximately 2 hours before presentation, while the patient was in flight, abdominal pain markedly worsened, vomiting increased, and she became confused and unresponsive. The flight was diverted to Boston. On examination by emergency medical services personnel, she was non-verbal and was moaning continuously. The blood pressure was 120/70 mm Hg, the pulse 52 beats per minute, and the respiratory rate 26 breaths per minute. The capillary blood glucose level was 116 mg per deciliter (6.4 mmol per liter). She was brought to the emergency department at this hospital by ambulance.

The patient's history was obtained from her husband through an interpreter. She had non-insulin-dependent (type 2) diabetes mellitus, hypertension, nephrolithiasis, and chronic kidney disease. Medications included enalapril, metformin, glimepiride, nimesulide, imipramine, aspirin, and ibuprofen. She had no known allergies. She was married and had children. She lived in Italy and did not speak English. She had vacationed in North America for 10 days, traveling to urban areas. She did not smoke, drink alcohol, or use illicit drugs, and there was no history of unusual ingestions.

On examination, the patient was incoherent and appeared agitated and uncomfortable, with frequent groaning. She was oriented to person only and opened her eyes to command. The blood pressure was 120/70 mm Hg, the pulse 52 beats per minute, the temperature 36.7°C, the respiratory rate 18 breaths per minute, and the oxygen saturation 95% while she was breathing ambient air. The pupils were 3 mm

in diameter and minimally reactive to light; the oral mucous membranes were dry, and the neck was supple. The abdomen was soft, without distention, rebound tenderness, or guarding. The skin was cool. The remainder of the general examination was normal. The neurologic examination was limited because of the patient's inability to follow commands; she withdrew all extremities to pain, and cranial nerves and strength appeared normal. Normal saline was rapidly infused, and dextrose, insulin, ondansetron, and morphine sulfate were administered intravenously. An electrocardiogram revealed atrial fibrillation at a rate of 115 beats per minute and a QRS duration of 94 msec, with a tremulous baseline possibly obscuring ST-segment depression in the inferior leads. Blood levels of calcium, triglycerides, glycated hemoglobin, and haptoglobin were normal, as were the results of liver-function tests; other test results are shown in Table 1. Placement of an indwelling urinary catheter was followed by placement of intravascular catheters in the right external jugular vein and the femoral artery.

Within 2 hours after the patient's arrival in the emergency department, tachypnea and increasing somnolence developed; results of venous oximetry are shown in Table 1. The trachea was intubated after the administration of etomidate and rocuronium, and 100% oxygen was administered and bicarbonate was infused. A chest radiograph showed no evidence of pneumonia or pleural effusion. There were ill-defined calcifications in the soft tissue of the left breast.

Approximately 3 hours after the patient's arrival, the rectal temperature decreased to 31.7°C and the blood pressure to 84/43 mm Hg. Norepinephrine bitartrate and bicarbonate were administered; fluids were warmed before infusion, and a blanket warmer was placed. Dark-brown gastric secretions that were positive for occult blood were aspirated through an orogastric tube; the gastric pH was 5.7.

*Dr. Raul N. Uppot:* Computed tomography (CT) of the abdomen and pelvis without the administration of intravenous or oral contrast material (Fig. 1) revealed pancreatic edema, peripancreatic fat stranding, a small amount of perihepatic and pericholecystic fluid without biliary ductal dilatation, some thickened walls in several loops of

small bowel, and an atrophic left kidney containing a nonobstructing calculus. CT of the chest revealed dependent atelectasis, with no focal consolidation, masses, or effusions, and calcifications of the left breast. CT of the brain was normal.

*Dr. Schoenfeld:* Cefepime, vancomycin, and metronidazole were administered intravenously. After laboratory results were known, sodium polystyrene sulfonate was given orally. Toxicologic screening of the blood and urine was negative.

The patient was admitted to the cardiac intensive care unit (ICU). Vasopressin, propofol, and calcium were added, and additional bicarbonate and glucose were administered. Eight hours after her presentation, continuous venovenous hemofiltration with bicarbonate solution was begun. Cultures of the blood and urine were obtained. Fourteen hours after presentation, the urine sodium level was 136 mmol per liter, and the urine creatinine level was 0.25 mg per milliliter. Echocardiography revealed normal global cardiac function, without pericardial effusion.

*Dr. Uppot:* Ultrasonography of the abdomen revealed small-volume ascites, nonspecific thickening of the gallbladder wall, and an atrophic left kidney; there was increased renal parenchymal echogenicity of both kidneys (Fig. 2).

*Dr. Schoenfeld:* During the first 17 hours, the patient had oliguria, with approximately 125 ml of urine excreted. Additional laboratory tests are shown in Table 1.

A diagnostic test was performed.

---

#### DIFFERENTIAL DIAGNOSIS

---

*Dr. Kamyar Kalantar-Zadeh:* The patient was an acutely ill 54-year-old woman with a medical history of type 2 diabetes, hypertension, kidney stones, and chronic kidney disease of unknown severity. She presented to the emergency department with deteriorating mental state, respiratory distress, and worsening gastrointestinal symptoms. Laboratory evaluation showed a profound leukocytosis with a left shift (increased levels of immature neutrophil forms circulating in the peripheral blood), an increase in pancreatic enzyme levels, severe metabolic acidosis with a markedly elevated serum lactate level, profound hyperphosphatemia, and oliguric kidney failure. Although it would be helpful to have a urinalysis, it was not

performed in the first 24 to 48 hours because of worsening oliguria, the need for other more urgent tests, and other priorities.

My initial differential diagnoses include severe lactic acidosis, probably resulting from sepsis, cardiogenic shock, or nonhypoxic causes (e.g., med-

ications and cancer); concurrent acute pancreatitis; and concomitant acute kidney injury, probably superimposed on preexisting chronic kidney disease, which could be a result of sepsis, the cardiorenal syndrome, rhabdomyolysis with hyperphosphatemia, or other causes (Table 2).

**Table 1. Laboratory Data.\***

Variable	Reference Range, Adults†	On Admission	17 Hr after Presentation
Hematocrit (%)	36.0–46.0 (women)	44.4	30.0
Hemoglobin (g/dl)	12.0–16.0 (women)	13.4	10.1
White-cell count (per mm <sup>3</sup> )	4500–11,000	34,800	32,100
Differential count (%)			
Neutrophils	40–70	79	
Band forms	0–10	2	
Lymphocytes	22–44	10	
Monocytes	4–11	5	
Eosinophils	0–8	1	
Myelocytes	0	2	
Metamyelocytes	0	1	
Platelet count (per mm <sup>3</sup> )	150,000–400,000	>483,000, with platelet clumps	179,000
Erythrocyte count (per mm <sup>3</sup> )	4,000,000–5,200,000	4,340,000	3,330,000
Mean corpuscular volume (μm <sup>3</sup> )	80–100	103	90
Mean corpuscular hemoglobin concentration (g/dl)	31.0–37.0	30.1	33.6
Smear description		Toxic granulations and increased burr cells present; 3+ hypochromasia; 1+ macrocytes	
Activated partial-thromboplastin time (sec)	21.0–33.0	36.2	26.4
Prothrombin time (sec)	11.0–13.7	15.7	14.3
International normalized ratio for prothrombin time		1.3	1.2
Sodium (mmol/liter)	135–145	146	140
Potassium (mmol/liter)	3.4–4.8	6.3 (not hemolyzed)	3.5
Chloride (mmol/liter)	100–108	83	88
Carbon dioxide (mmol/liter)	23.0–31.9	<2.0	16.0
Urea nitrogen (mg/dl)	8–25	94	58
Creatinine (mg/dl)	0.60–1.50	7.88	3.94
Glucose (mg/dl)	70–110	168	316
Glycated hemoglobin (%)	3.80–6.40	5.70	
Protein (g/dl)			
Total	6.0–8.3	6.7	4.2
Albumin	3.3–5.0	4.6	2.9
Globulin	2.3–4.1	2.1	1.3
Calcium (mg/dl)	8.5–10.5	9.5	6.6 (7.5 hr after presentation)

Table 1. (Continued.)			
Variable	Reference Range, Adults†	On Admission	17 Hr after Presentation
Phosphorus (mg/dl)	2.6–4.5	19.3	
Magnesium (mmol/liter)	0.7–1.0	1.1	
Lactate dehydrogenase (U/liter)	110–210		515
Lipase (U/liter)	13–60	595	88
Amylase (U/liter)	3–100	386	276
Lactate (mmol/liter)	0.5–2.2	20.3	13.7
Troponin T (ng/ml)	<0.03	0.03	
Creatine kinase (U/liter)	40–150	656	
Osmolality (mOsm/kg of water)	280–296		354 (11 hr after presentation)
Blood gases			
Fraction of inspired oxygen		0.21 (ambient air)	0.40
Source		Venous	Unspecified
pH	7.30–7.40 (venous); 7.32–7.45 (unspecified)	6.62	7.38
Partial pressure of carbon dioxide (mm Hg)	38–50 (venous); 35–50 (unspecified)	18	27
Partial pressure of oxygen (mm Hg)	35–50 (venous); 40–90 (unspecified)	73	156
Base excess (mmol/liter)		–35.1	–8.6

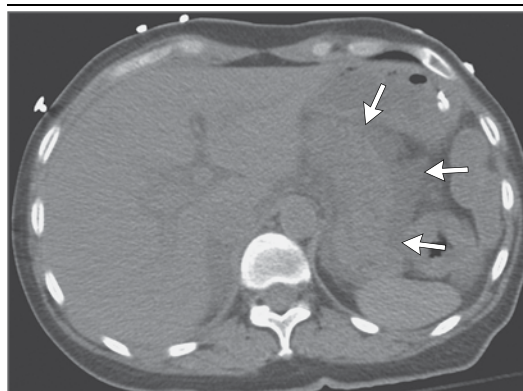\* To convert the values for urea nitrogen to millimoles per liter, multiply by 0.357. To convert the values for creatinine to micromoles per liter, multiply by 88.4. To convert the values for glucose to millimoles per liter, multiply by 0.05551. To convert the values for calcium to millimoles per liter, multiply by 0.250. To convert the values for phosphorus to millimoles per liter, multiply by 0.3229. To convert the values for magnesium to milligrams per deciliter, divide by 0.4114. To convert the values for lactate to milligrams per deciliter, divide by 0.1110.

† Reference values are affected by many variables, including the patient population and the laboratory methods used. The ranges used at Massachusetts General Hospital are for adults who are not pregnant and do not have medical conditions that could affect the results. They may therefore not be appropriate for all patients.

#### ACID–BASE DISORDERS

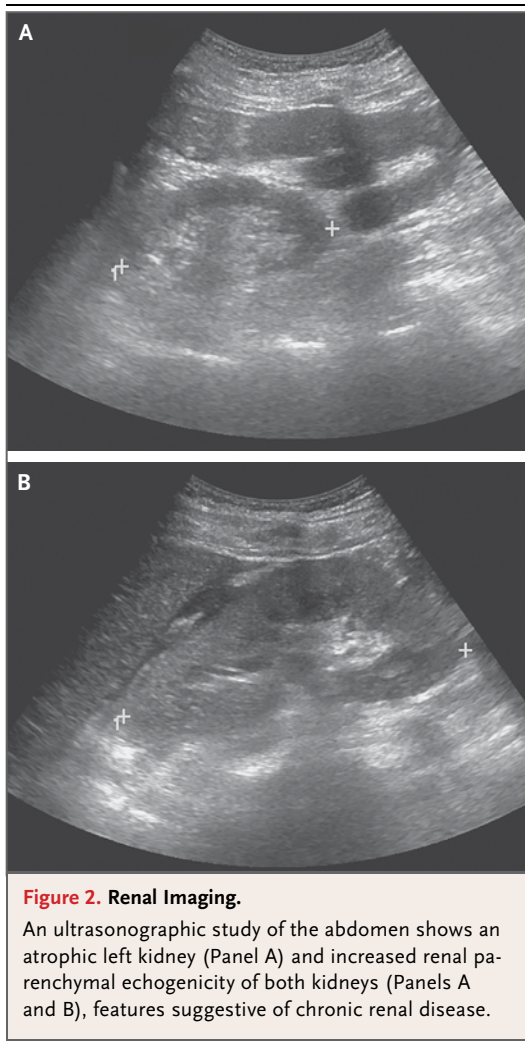
Some of the patient's test results are markedly abnormal. These include a profoundly low blood pH (6.62), a markedly low serum bicarbonate level (<2 mmol per liter; target range, 23 to 25), and a low partial pressure of carbon dioxide ( $P_{CO_2}$ ) (18 mm Hg). Given the severely acidemic pH, which is unusual even for a venous blood sample,<sup>1</sup> we should first confirm that this blood-gas analysis is correct. The concentration of hydrogen ions in the patient's blood is calculated (with the modified Henderson's equation<sup>2</sup>) to be 216 nmol per liter, which corresponds to a blood pH between 6.6 and 6.7 and confirms the accuracy of the reported blood-gas data and suggests that she had an exceptionally severe metabolic acidosis.

The patient had a markedly elevated anion gap of 61 mmol per liter (reference range, 8 to 12), indicating that she had a profound anion-gap meta-



**Figure 1. Abdominal Imaging.**

A CT scan of the abdomen and pelvis, without intravenous or oral contrast material, reveals pancreatic edema and peripancreatic fat stranding and fluid (arrows), features consistent with acute pancreatitis. No pseudocyst or gallstones were visualized.



bolic acidosis. Conditions causing this degree of acidosis include lactic acidosis, aspirin overdose, methanol or ethylene glycol toxicity, diabetic ketoacidosis, and uremia. Lactic acidosis in this patient was corroborated by a markedly elevated serum lactate level (>20 mmol per liter); other causes of metabolic acidosis could not be substantiated by the test results.

Estimating this patient's osmolal gap is another way to refine the differential diagnosis. She had a mildly elevated osmolal gap (the difference between the measured and calculated serum osmolality) of 18 mOsm per kilogram of water (reference range, 5 to 15). A slightly elevated or borderline high osmolal gap is usually caused by either lactic acidosis or ketoacidosis; methanol or ethylene glycol ingestion often leads to a more

profound rise in the osmolal gap, making such ingestion a less likely diagnosis in this case.

Furthermore, the patient's anion gap is approximately 50 mmol per liter above the normal level, and the serum bicarbonate level is approximately 20 mmol per liter below the normal level (i.e., the deviation from normal of the anion gap is more than two times as high as the deviation from normal of the bicarbonate level). This suggests that she could have a concomitant metabolic alkalosis, probably because of repeated vomiting and loss of hydrochloric acid. Nevertheless, the patient's profound hyperphosphatemia may have contributed to the disproportionately high anion gap.<sup>3</sup>

#### RESPIRATORY ACID-BASE DISORDERS

Does this patient have a concurrent respiratory acid-base disorder? We would expect that for each 10 mmol per liter decrease from normal in the bicarbonate level, a compensatory decrease in the  $P_{CO_2}$  of at least 12 mm Hg would ensue.<sup>4</sup> Since the patient's serum bicarbonate level was 22 mmol per liter lower than the target level of 24 mmol per liter, the expected drop in the  $P_{CO_2}$  should have been approximately 26 mm Hg. Indeed, despite her acute illness and altered mental state, she was capable of lowering the  $P_{CO_2}$  by 22 mm Hg (from a normal value of 40 mm Hg to 18 mm Hg), probably by breathing deeply and increasing her respiratory rate in an attempt to compensate for the marked decrease in the serum bicarbonate level. Her remarkable and effective compensatory hyperventilation, classically known as Kussmaul respiration, is often perceived by clinicians as "respiratory distress."<sup>5</sup> In addition, the chest radiograph obtained on the patient's arrival in the emergency department was normal, providing further support that she probably had no respiratory disease. Her need for intubation and mechanical ventilation was probably the result of her worsening mental state, which could have been aggravated by the administration of morphine in association with renal insufficiency.<sup>6</sup>

#### SEVERE ACIDEMIA

Many, if not all, features of this patient's presentation can be explained by profound acidemia (Fig. 3). Altered mental status, including lethargy, stupor, and even coma, can be a direct consequence of acidosis.<sup>7</sup> Acidemia may lead to increased vasodilatation and warm skin, which the patient had

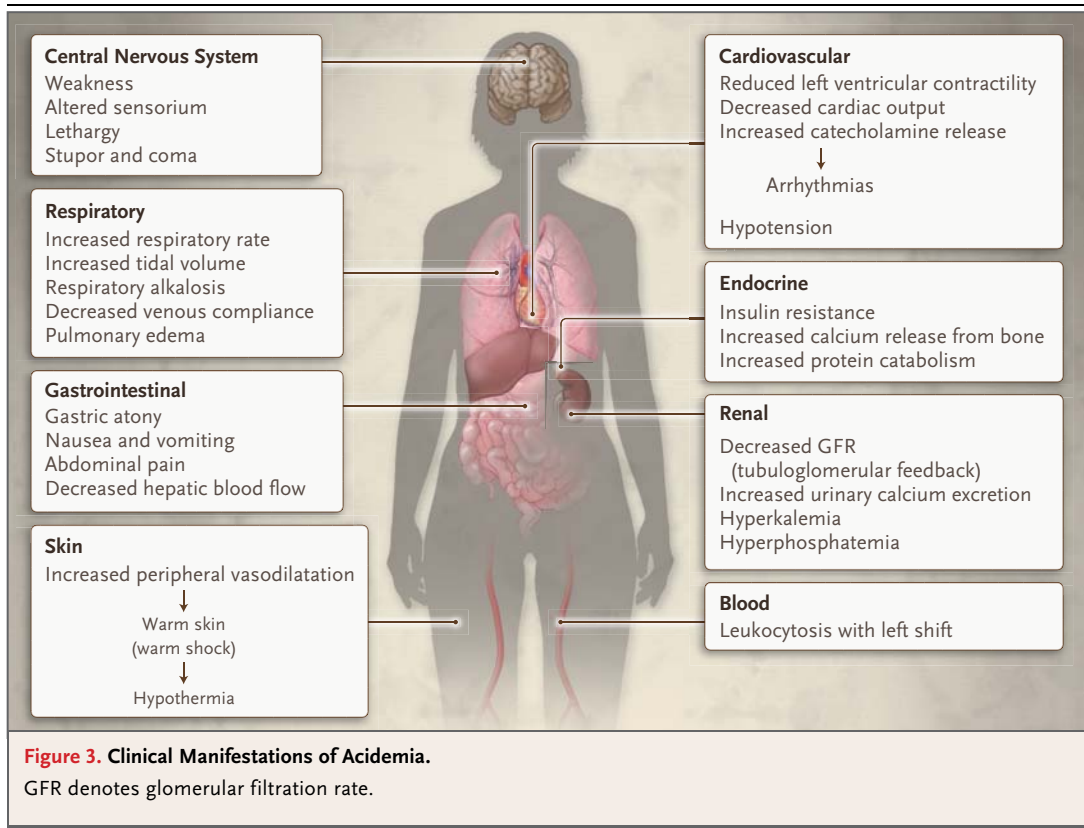
**Table 2. Differential Diagnoses.**

Diagnosis	Findings More Consistent with Diagnosis	Findings Less Consistent with Diagnosis
Sepsis (e.g., pyelonephritis and intraabdominal infection, such as emphysematous pyelonephritis)	Leukocytosis, lactic acidosis (type A), hypothermia, altered mental state	Initial normal blood pressure, no identifiable source of infection
Cardiogenic shock (e.g., acute coronary syndrome)	Lactic acidosis (type A), arrhythmias, pre-existing vascular calcification, pulmonary edema	Initial normal blood pressure, normal troponin level, normal echocardiogram, hypothermia, profound leukocytosis
Metformin-associated lactic acidosis	Metformin therapy, lactic acidosis (type B), profound acidemia, altered mental state, preexisting renal insufficiency	Profound leukocytosis, prominent gastrointestinal symptoms
Cancer (e.g., lymphoma and leukemia)	Hyperphosphatemia (possible tumor lysis syndrome), leukocytosis (with leukemoid reaction), lactic acidosis (type B), kidney failure	Prominent gastrointestinal symptoms, no other identifiable clues to malignant conditions
Overdose of salicylates (e.g., acetylsalicylic acid)	History of aspirin intake, anion-gap acidosis, hyperventilation	No respiratory alkalosis, too-severe lactic acidosis, no initial respiratory alkalosis, negative toxicologic screening
Intoxication with ethylene glycol, methanol, or paraldehyde	Anion-gap acidosis, altered mental state, worsening kidney function	Negative toxicologic screening, too-small osmolal gap, too-severe lactate acidosis
Mesenteric ischemia	Severe gastrointestinal symptoms, leukocytosis, hypothermia, lactic acidosis (type A), altered mental state	Upper gastrointestinal bleeding, non-supporting imaging studies
Rhabdomyolysis	Hyperphosphatemia, large anion gap, increased creatine kinase level	Profound leukocytosis, no other supporting clues
Diabetic ketoacidosis	History of diabetes, abdominal pain, anion-gap acidosis	Normal glucose level, normal glycated hemoglobin, high lactate level (too high for diabetic ketoacidosis)
Acute pancreatitis	Gastrointestinal symptoms, elevated amylase and lipase levels, evidence on imaging studies	A pattern of abdominal pain not typical for pancreatitis
Acute kidney injury, superimposed on chronic kidney disease	History of chronic kidney disease, history of nephrolithiasis with atrophic left kidney, type 2 diabetes, history of intake of an angiotensin-converting-enzyme inhibitor and nonsteroidal antiinflammatory drugs, hyperkalemia, hyperphosphatemia, low urinary creatinine level	Normal hemoglobin level

reported during the 3 days before hospitalization. However, by the time the patient arrived at the emergency department, the acidosis had dramatically worsened and had most likely led to her paradoxical hypothermia, which is a known complication of profound acidosis.<sup>7</sup> She also had some of the cardiovascular consequences of acidosis, including cardiac failure and catecholamine release, which led to arrhythmia and respiratory compromise. Her atrial fibrillation could be a direct complication of acute acidemia.

Although we need to rule out cardiogenic or septic shock, which could explain the acute kidney injury, severe acidosis could lead to a decline

in the glomerular filtration rate (GFR).<sup>7</sup> Given the patient's reported medical history of chronic kidney disease, probably caused by diabetic or tubulointerstitial nephropathy or hypertensive nephrosclerosis and the administration of an angiotensin-converting-enzyme (ACE) inhibitor and nonsteroidal antiinflammatory drugs (NSAIDs), she was probably susceptible to the development of superimposed acute kidney injury from any of these events.<sup>8</sup> Her gastrointestinal manifestations were impressive and most likely were due to a concurrent acute pancreatitis. Nevertheless, we should note again that acidemia could cause gastric atony, nausea, vomiting, and abdominal



pain. Finally, the remarkable leukocytosis with a left shift can also be explained by severe acidosis<sup>9</sup>; however, an infectious disease is a more likely explanation, as are malignant conditions such as leukemia and lymphoma.

#### ANION-GAP METABOLIC ACIDOSIS

What could explain anion-gap metabolic acidosis with an elevated serum lactate level in this patient? One possible cause of a classic (type A) lactic acidosis is impaired tissue perfusion that typically happens in patients with septic or cardiogenic shock or during cardiopulmonary arrest. However, another likely cause of anion-gap metabolic acidosis in this patient is nonhypoxic (type B) lactic acidosis. Impaired lactate metabolism can occur in association with the administration of certain medications (e.g., metformin, salicylate, isoniazid, and zidovudine) or in association with certain cancers (e.g., lymphoma and leukemia), among other reasons.<sup>10</sup> This patient had been taking metformin, which, like other biguanides (e.g., phenformin and buformin), can lead to the increased generation and accumulation of lactate by re-

ducing gluconeogenesis and glycogenolysis, inhibiting oxygen consumption, and impairing mitochondrial function in the liver and other organs.<sup>11</sup> In fact, phenformin and buformin were removed from the market because they are associated with an unacceptably high risk of lactic acidosis.<sup>12</sup>

This patient had a high risk of metformin accumulation, given her history of chronic kidney disease, and this is corroborated by seemingly normalized glucose and glycated hemoglobin levels, which probably resulted from the progression of renal insufficiency.<sup>13,14</sup> The profound acidemia with a massive decrease in the serum bicarbonate level and a markedly elevated serum lactate level is consistent with other reports of metformin-associated acidosis.<sup>11,15</sup> A case series comparing metformin-associated acidosis with other types of lactic acidosis, such as those associated with postcardiac arrest, septic shock, cardiogenic shock, mesenteric ischemia, and hemorrhagic shock, described only metformin as being associated with a mean blood pH below 7.0, as in this patient.<sup>16</sup> Survival rates associated

with the toxic effects of metformin are generally better, despite a more severe acidemia, than the rates associated with other causes of lactic acidosis.<sup>16</sup> Therefore, I expect and certainly hope that this patient survived, especially since she underwent continuous venovenous hemodiafiltration therapy for oliguric renal failure, which could also effectively lower the metformin level despite its large volume of distribution.<sup>11,17</sup> Not many laboratories can measure metformin levels rapidly; if such testing is available, it is usually performed as a late confirmatory test.<sup>17</sup>

In my experience and on the basis of the data reviewed in the literature,<sup>16,17</sup> metformin overdose or accumulation as the cause of lactic acidosis is highly likely in any patient who has most or all of the following five criteria even if the metformin level is not known: a history of metformin administration (e.g., in a patient with type 2 diabetes), a markedly elevated lactate level (>15 mmol per liter) and a large anion gap (>20 mmol per liter), severe acidemia (pH <7.1), a very low serum bicarbonate level (<10 mmol per liter), and a history of renal insufficiency (estimated GFR, <45 ml per minute per 1.73 m<sup>2</sup> of body-surface area; or serum creatinine level, >2.0 mg per deciliter [ $>177$   $\mu$ mol per liter]).

This patient has all these features. The acute pancreatitis also could have been caused by metformin accumulation.<sup>12,18</sup> Therefore, I expect that the diagnostic test in this case was a high metformin level or maybe a novel surrogate of the metformin level that I am not aware of.

*Dr. Eric S. Rosenberg (Pathology):* Dr. Schoenfeld, what was your initial impression when you evaluated this patient?

*Dr. Schoenfeld:* Our initial impression was that the renal failure was due to a combination of factors, including poor oral intake and multiple nephrotoxic agents, including an ACE inhibitor and NSAIDs. We believed that the lactic acidosis was probably a result of metformin accumulation in association with the renal failure. Given the CT findings of peripancreatic fat stranding and pancreatic edema, we wondered whether the initial insult may have been pancreatitis, which led to the abdominal pain, nausea, and reduced oral intake. However, we could not be certain that pancreatitis was the primary insult; alternatively, the abdominal pain and pancreatitis could have been a result of severe acidemia and the toxic effects of metformin.

---

#### CLINICAL DIAGNOSIS

---

Lactic acidosis caused by the toxic effects of metformin.

---

#### DR. KAMYAR KALANTAR-ZADEH'S DIAGNOSIS

---

Type B lactic acidosis caused by metformin accumulation.

---

#### PATHOLOGICAL DISCUSSION

---

*Dr. Kent B. Lewandrowski:* The patient's plasma metformin level was 23  $\mu$ g per milliliter (reference range, 1 to 2), which explains her presentation. The clinical thinking at the time was that her exposure to multiple nephrotoxic drugs, including aspirin, ibuprofen, and enalapril, resulted in acute kidney injury. Metformin is excreted unmetabolized in the urine. Therefore, the patient's impaired renal function resulted in the accumulation of metformin in the plasma, causing lactic acidosis. In patients who have toxic effects of metformin, the mechanism of lactic acidosis is multifactorial, including enhanced conversion of glucose to lactate in the small intestine and inhibition of gluconeogenesis by lactate, pyruvate, and alanine. As in this patient, the toxic effects of metformin typically present with nausea and abdominal pain,<sup>19</sup> and the mortality rate is high, approaching 50%. The diagnosis requires a high index of suspicion and a consideration of clinical and laboratory findings and the patient's medication history. Measurement of a metformin level will firmly establish the diagnosis; however, this approach is usually impractical because few hospitals offer this test in-house and obtaining results from a reference laboratory may take several days.

*Dr. Schoenfeld:* The patient was admitted to the cardiac ICU, and continuous venovenous hemofiltration was continued. Within the first 24 hours after admission, her mental status improved dramatically. She was extubated 1 day after admission. Within the next 48 hours, her metabolic abnormalities started to normalize and she began to make copious amounts of urine. At that point, continuous venovenous hemofiltration was discontinued and she was weaned off vasopressin. Out of concern for infection, she had been started on broad-spectrum antibiotics at the time of admission, but after 48 hours, cultures of blood and



urine remained negative and the antibiotics were discontinued. She was transferred to the general medical unit, where her hypertension was managed with a calcium-channel blocker. Her renal function completely normalized. She was discharged from the hospital 1 week after admission, and she returned home to Italy. We received notification from her primary care doctor 1 week later that she was doing well and had resumed her normal daily activities.

## FINAL DIAGNOSIS

### Toxic effects of metformin.

This case was presented as part of the Harvard Medical School postgraduate course Internal Medicine: Comprehensive Review and Update, directed by Ravi I. Thadhani, M.D., M.P.H., Sekar Kathiresan, M.D., and Dennis Ausiello, M.D.

Dr. Uppot reports receiving payment for reviewing testimony for a legal case involving renal biopsy. No other potential conflict of interest relevant to this article was reported.

Disclosure forms provided by the authors are available with the full text of this article at NEJM.org.

## REFERENCES

1. Adrogué HJ, Rashad MN, Gorin AB, Yacoub J, Madias NE. Assessing acid-base status in circulatory failure: differences between arterial and central venous blood. *N Engl J Med* 1989;320:1312-6.
2. Kalantar-Zadeh K, Mehrotra R, Fouque D, Kopple JD. Metabolic acidosis and malnutrition-inflammation complex syndrome in chronic renal failure. *Semin Dial* 2004;17:455-65.
3. Kraut JA, Madias NE. Serum anion gap: its uses and limitations in clinical medicine. *Clin J Am Soc Nephrol* 2007;2:162-74.
4. Kurtz I. Clinical approach to the diagnosis of acid-base disorders. *Can Med Assoc J* 1979;121:157-8.
5. Adolf Kussmaul (1822-1902) — country doctor to clinical professor. *JAMA* 1964;189:58-9.
6. Fainsinger RL, Miller MJ, Bruera E. Morphine intoxication during acute reversible renal insufficiency. *J Palliat Care* 1992;8:52-3.
7. Cogan MG, ed. Fluid & electrolytes: physiology & pathophysiology. San Mateo, CA: Appleton & Lange, 1991:203-24.
8. Rifkin DE, Coca SG, Kalantar-Zadeh K. Does AKI truly lead to CKD? *J Am Soc Nephrol* 2012;23:979-84.
9. Tullis JL. The leukocytosis of diabetic acidosis. *Am J Med Sci* 1948;215:424-6.
10. Caspar CB, Oelz O. Lactic acidosis in malignant lymphoma. *Am J Med* 1991;91:197-8.
11. Vecchio S, Protti A. Metformin-induced lactic acidosis: no one left behind. *Crit Care* 2011;15:107.
12. Fimognari FL, Corsonello A, Pastorell R, Antonelli-Incalzi R. Metformin-induced pancreatitis: a possible adverse drug effect during acute renal failure. *Diabetes Care* 2006;29:1183.
13. Kovesdy CP, Park JC, Kalantar-Zadeh K. Glycemic control and burnt-out diabetes in ESRD. *Semin Dial* 2010;23:148-56.
14. Kalantar-Zadeh K. A critical evaluation of glycosylated protein parameters in advanced nephropathy: a matter of life or death: A1C remains the gold standard outcome predictor in diabetic dialysis patients. *Counterpoint. Diabetes Care* 2012;35:1625-8.
15. Protti A, Russo R, Tagliabue P, et al. Oxygen consumption is depressed in patients with lactic acidosis due to biguanide intoxication. *Crit Care* 2010;14:R22.
16. Friesecke S, Abel P, Roser M, Felix SB, Runge S. Outcome of severe lactic acidosis associated with metformin accumulation. *Crit Care* 2010;14:R226.
17. Nguyen HL, Concepcion L. Metformin intoxication requiring dialysis. *Hemodial Int* 2011;15:Suppl 1:S68-S71.
18. Mallick S. Metformin induced acute pancreatitis precipitated by renal failure. *Postgrad Med J* 2004;80:239-40.
19. Chu J, Stolbach A. Metformin poisoning. In: UpToDate, 7.0 ed. Waltham, MA: UpToDate, 2012 ([http://www.uptodate.com/contents/metformin-poisoning?source=search\\_result&search=Metformin+poisoning&selectedTitle=1%7E5](http://www.uptodate.com/contents/metformin-poisoning?source=search_result&search=Metformin+poisoning&selectedTitle=1%7E5)).

Copyright © 2013 Massachusetts Medical Society.

### LANTERN SLIDES UPDATED: COMPLETE POWERPOINT SLIDE SETS FROM THE CLINICOPATHOLOGICAL CONFERENCES

Any reader of the *Journal* who uses the Case Records of the Massachusetts General Hospital as a teaching exercise or reference material is now eligible to receive a complete set of PowerPoint slides, including digital images, with identifying legends, shown at the live Clinicopathological Conference (CPC) that is the basis of the Case Record. This slide set contains all of the images from the CPC, not only those published in the *Journal*. Radiographic, neurologic, and cardiac studies, gross specimens, and photomicrographs, as well as unpublished text slides, tables, and diagrams, are included. Every year 40 sets are produced, averaging 50-60 slides per set. Each set is supplied on a compact disc and is mailed to coincide with the publication of the Case Record.

The cost of an annual subscription is \$600, or individual sets may be purchased for \$50 each. Application forms for the current subscription year, which began in January, may be obtained from the Lantern Slides Service, Department of Pathology, Massachusetts General Hospital, Boston, MA 02114 (telephone 617-726-2974) or e-mail [Pathphotoslides@partners.org](mailto:Pathphotoslides@partners.org).