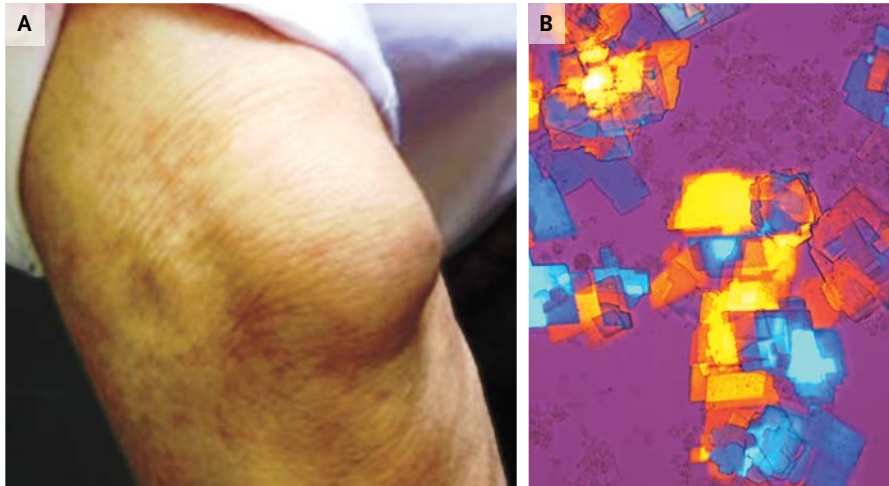


## IMAGES IN CLINICAL MEDICINE

Lindsey R. Baden, M.D., *Editor*

## Unusual Bursal Fluid



**A** 73-YEAR-OLD MAN WITH SEROPOSITIVE RHEUMATOID ARTHRITIS AND extraarticular involvement (rheumatoid nodules on the right elbow) presented with persistent, painless swelling of the left elbow (Panel A). His medical history was unremarkable except for hypertension. The disease had been in clinical and serologic remission since treatment with methotrexate had been initiated. Findings on ultrasonographic examination were consistent with left olecranon bursitis. On aspiration, the bursal fluid appeared viscous, thick, and purulent. The bursal white-cell count was 2700 per cubic millimeter. Microbial cultures were negative. Compensated polarized light microscopy revealed a small number of leukocytes and large, rectangular, platelike crystals with strong birefringence (both positive and negative) and notched corners (Panel B), features characteristic of cholesterol crystals. The fasting serum cholesterol level was normal. Since there was no improvement with local injection of glucocorticoids, the patient was referred for surgical removal of the bursa. Cholesterol crystals are occasionally seen in the bursal fluid of patients who have rheumatoid arthritis.

Elena Bartoloni, M.D.  
Giulia Mirabelli, M.D.

University of Perugia  
Perugia, Italy  
elena.bartolonibocci@unipg.it

DOI: 10.1056/NEJMicm1304040

Copyright © 2013 Massachusetts Medical Society.