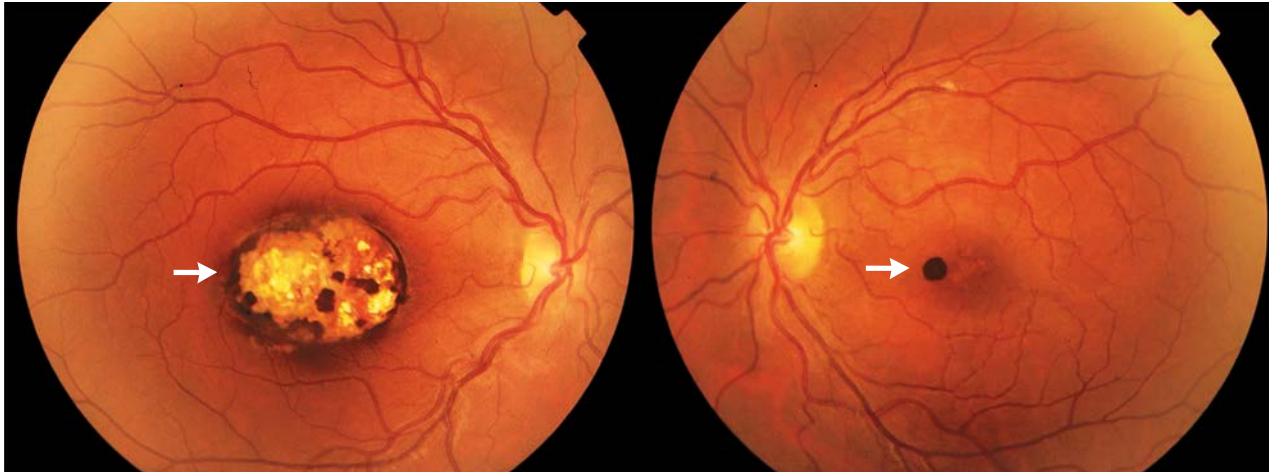


IMAGES IN CLINICAL MEDICINE

Lindsey R. Baden, M.D., *Editor*

## Chorioretinal Toxoplasmosis



**A** 30-YEAR-OLD MAN WAS INCIDENTALLY FOUND ON FUNDUSCOPIC EXAMINATION to have pigmented and sharply demarcated chorioretinal lesions involving the macular region. The lesions measured 5 mm in the right eye and less than 1 mm in the left eye (white arrows). There was no evidence of associated vitritis. This finding was consistent with scarring caused by inactive chorioretinal toxoplasmosis. The rest of the ophthalmologic examination was notable for low visual acuity in the right eye, at 6/150, associated with nystagmus; the best corrected visual acuity in the left eye was 6/24. The patient reported that he had always had poor bilateral vision and had not noted any recent visual changes. Serologic testing was positive for *Toxoplasma gondii* IgG antibody (low level) and negative for IgM antibody. Such lesions are typical of acquired or congenital inactive chorioretinal toxoplasmosis. The presence of nystagmus and bilateral macular involvement are suggestive of a congenital origin.

DOI: 10.1056/NEJMicm1306819

Copyright © 2014 Massachusetts Medical Society.

Zouheir Hafidi, M.D.

Rajae Daoudi, M.D.

University of Mohammed V Souissi  
Rabat, Morocco  
zouheirhafidi@gmail.com