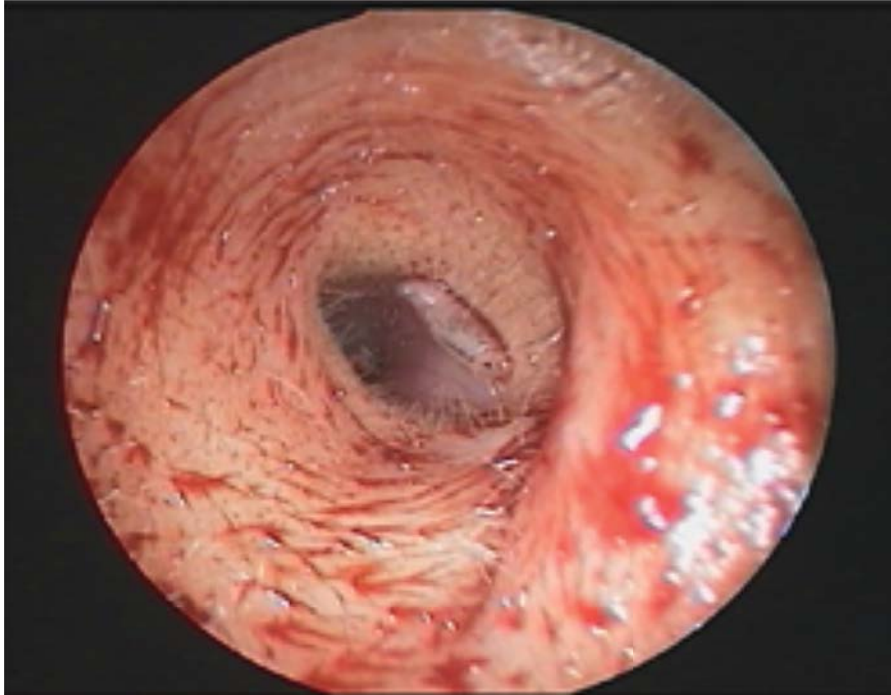


IMAGES IN CLINICAL MEDICINE

Lindsey R. Baden, M.D., *Editor*

An Unusual Auricular Foreign Body



A 48-YEAR-OLD WOMAN WHO HAD WORN A HEARING AID IN HER LEFT EAR for many years presented to the emergency department with severe otalgia of 1 day's duration. Bloody otorrhea in the left ear was noted after the hearing aid was removed. Physical examination showed a fruit-fly larva moving in the left external auditory canal (see video). The skin over the floor of the auditory canal, close to the eardrum, was eroded. The larva was removed uneventfully, and the patient received topical antibiotic treatment with ofloxacin. The otalgia resolved immediately, and 2 weeks after treatment, the erosion in the left auditory canal was completely healed.

DOI: 10.1056/NEJMicm1212769

Copyright © 2014 Massachusetts Medical Society.

Hui-Ming Feng, M.D.
Cheng-Ping Shih, M.D.

Tri-Service General Hospital
Taipei, Taiwan
zhengping@mail.ndmctsgh.edu.tw