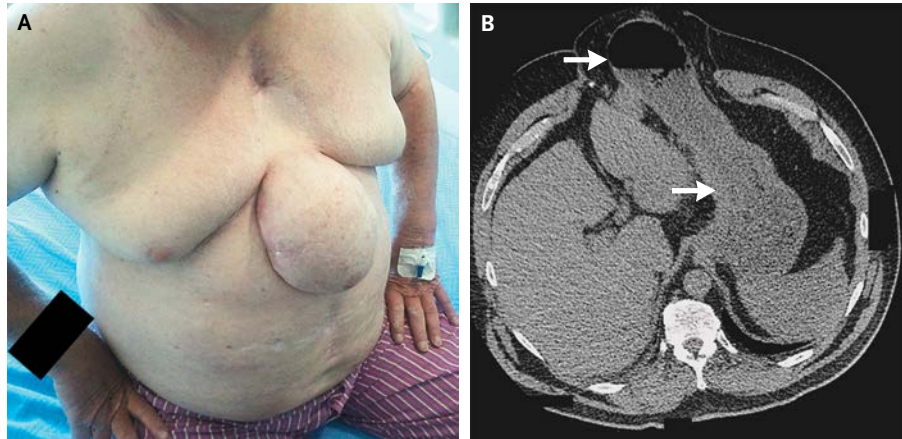


IMAGES IN CLINICAL MEDICINE

Lindsey R. Baden, M.D., *Editor*

Transsternal Gastric Hernia



Eoin Daniel O'Sullivan, M.B.
Sarah Margaret Moran, M.B.

Cork University Hospital
Cork, Ireland

A 55-YEAR-OLD MAN WITH DIABETES PRESENTED WITH SEVERE REFLUX, chronic cough, and aspiration pneumonia. An easily reducible hernia measuring 10 cm by 15 cm was noted in the area of the sternal defect (Panel A). Three years earlier, he had undergone coronary-artery bypass grafting, which was complicated by impaired sternal wound healing. Débridement was performed, sternotomy wires were removed, and care was provided for the open wound until an omental flap could be placed to achieve wound closure. Computed tomography of the thorax revealed anterior gastric herniation through the defect (Panel B). Given the complexity of the surgical repair required and the patient's coexisting conditions, a conservative approach of weight loss, treatment with a proton-pump inhibitor, and the use of a truss was pursued. At 7 months, the patient was asymptomatic and free of further complications.

DOI: 10.1056/NEJMicm1309719

Copyright © 2014 Massachusetts Medical Society.