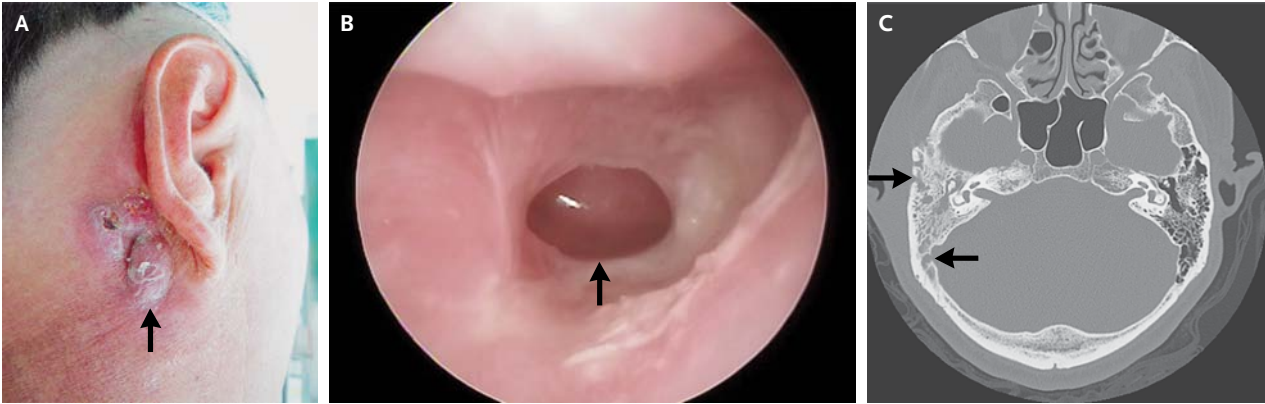


## IMAGES IN CLINICAL MEDICINE

## Mastoiditis



Yi-Ju Liao, M.D.  
Tien-Chen Liu, M.D., Ph.D.  
National Taiwan University Hospital  
Taipei, Taiwan  
liuent@ntu.edu.tw

A 60-YEAR-OLD MAN PRESENTED WITH A 10-YEAR HISTORY OF INTERMITTENT otorrhea of the right ear and a 2-month history of swelling of the right postauricular area. Physical examination revealed postauricular swelling with an erythematous skin change behind the right ear (Panel A, arrow). Otoscopic examination revealed a perforation in the lower part of the tympanic membrane, with discharge (Panel B, arrow). Audiometry revealed conductive hearing loss in the right ear. High-resolution computed tomography of the temporal bone (axial view) revealed high soft-tissue density lesions in the right tympanic cavity and in the mastoid air cells. Multifocal cortical defects were noted on the outer surface of the temporal bone and on the inner aspect facing the sigmoid sinus (Panel C, arrows). A diagnosis of chronic suppurative otitis media complicated by acute mastoiditis was made. This should be differentiated from other infections, such as parotitis, postauricular cellulitis, and lymphadenitis. The patient underwent tympanoplasty with mastoidectomy. During surgery, abundant granulation tissues filling the mastoid air cells and tympanic cavity were found and removed. The postauricular swelling and tenderness subsided gradually after treatment. His hearing also improved.

DOI: 10.1056/NEJMicm1205007

Copyright © 2013 Massachusetts Medical Society.