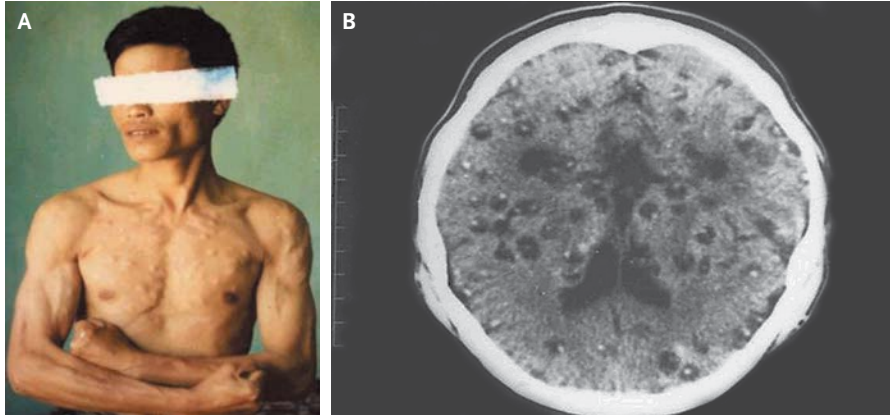


IMAGES IN CLINICAL MEDICINE

Multiple Palpable Cysts



A 42-YEAR-OLD MAN PRESENTED WITH SEIZURES AND APPROXIMATELY 300 palpable intramuscular cysts, with 54 cysts on his head, face, and neck, 110 on his chest and back, 86 on his arms, and 52 on his legs (Panel A). During the 3 years preceding presentation, he reported having a chronic headache and witnessing the development of intramuscular cystic nodules on his arms and his upper body (measuring 0.5 to 0.7 cm in diameter and 0.5 to 2.0 cm in diameter, respectively). Proglottids could be seen in his feces. A subcutaneous biopsy was performed, and a scolex with suckers and hooklets typical of the tapeworm *Taenia solium* were detected. A cranial computed tomographic scan was obtained and showed numerous neurocysticercosis cysts (measuring 3 to 5 mm in diameter) in his brain, containing living, dead, calcified, and mummified forms of the parasite (Panel B). The patient was given a single dose of praziquantel on the first day, followed by three rounds of treatment with albendazole administered for 30 days, withheld for 10 days, and then restarted. After 4 months of treatment, his headaches and seizures resolved, and resolution of the cysts could be seen on magnetic resonance imaging. The patient has recovered and has reported having no further seizures.

DOI: 10.1056/NEJMicm1205125

Copyright © 2013 Massachusetts Medical Society.

Nguyen De, M.D., Ph.D.

Hanoi Medical University
Hanoi, Vietnam

Thanh Hoa Le, D.V.M., Ph.D.

Institute of Biotechnology
Hanoi, Vietnam