

## BRIEF REPORT

# Family Cluster of Middle East Respiratory Syndrome Coronavirus Infections

Ziad A. Memish, M.D., Alimuddin I. Zumla, M.D., Ph.D., Rafat F. Al-Hakeem, M.D.,  
Abdullah A. Al-Rabeeah, M.D., and Gwen M. Stephens, M.D.

## SUMMARY

A human coronavirus, called the Middle East respiratory syndrome coronavirus (MERS-CoV), was first identified in September 2012 in samples obtained from a Saudi Arabian businessman who died from acute respiratory failure. Since then, 49 cases of infections caused by MERS-CoV (previously called a novel coronavirus) with 26 deaths have been reported to date. In this report, we describe a family case cluster of MERS-CoV infection, including the clinical presentation, treatment outcomes, and household relationships of three young men who became ill with MERS-CoV infection after the hospitalization of an elderly male relative, who died of the disease. Twenty-four other family members living in the same household and 124 attending staff members at the hospitals did not become ill. MERS-CoV infection may cause a spectrum of clinical illness. Although an animal reservoir is suspected, none has been discovered. Meanwhile, global concern rests on the ability of MERS-CoV to cause major illness in close contacts of patients.

MERS-CoV WAS FIRST REPORTED IN SEPTEMBER 2012 IN SAMPLES OBTAINED from a Saudi Arabian businessman who died from acute respiratory and renal failure.<sup>1</sup> As of May 28, 2013, a total of 49 cases of human MERS-CoV infection with 26 deaths have been reported to the World Health Organization (WHO). MERS-CoV is the first betacoronavirus belonging to lineage C that is known to infect humans.<sup>2</sup> It belongs to the Coronaviridae family, a group of large, enveloped single-stranded RNA viruses that are known for their genomic plasticity and their ability to cause a range of infections in mammalian and avian hosts. MERS-CoV is considered distinct<sup>3</sup> from the coronavirus responsible for the severe acute respiratory syndrome (SARS-CoV), which is a virulent, transmissible human pathogen that first emerged in southern China in the fall of 2002.<sup>4</sup> By February 2003, it had spread from Guangdong Province to nearby Hong Kong and Vietnam and then on to more than 30 countries. Before SARS-CoV disappeared in the summer of 2003, the WHO documented 8000 infections and 774 deaths, involving many health care workers and family members of patients.<sup>4</sup> MERS-CoV appears to be as virulent as SARS-CoV but is distinguished by the relative absence of severe disease among the close contacts of patients, except among those with immunosuppression.

We report a family cluster of MERS-CoV infections that occurred in November 2012: three confirmed cases and one probable case in an extended family living in urban Riyadh. Included are data on the clinical presentation, treatment outcomes, and household relationships of three young men who became ill with MERS-CoV infection after the hospitalization of an elderly male relative.

From the Global Center for Mass Gatherings Medicine (Z.A.M., A.I.Z., R.F.A.-H., A.A.A.-R., G.M.S.), the Ministry of Health (Z.A.M., R.F.A.-H., A.A.A.-R., G.M.S.), and Al-Faisal University (Z.A.M.) — all in Riyadh, Saudi Arabia; and the Division of Infection and Immunity, University College London, and Department of Medical Microbiology, UCL Hospitals NHS Foundation Trust, London (A.I.Z.). Address reprint requests to Dr. Memish at WHO Collaborating Center for Mass Gathering Medicine, Ministry of Health, Riyadh 11176, Saudi Arabia, or at [zmemish@yahoo.com](mailto:zmemish@yahoo.com).

This article was published on May 29, 2013, at [NEJM.org](http://NEJM.org).

*N Engl J Med* 2013;368:2487-94.

DOI: 10.1056/NEJMoal1303729

Copyright © 2013 Massachusetts Medical Society.

## CASE REPORTS

Figure 1 illustrates the case progressions for the four patients with either confirmed or probable MERS-CoV infection. Patient 1, a 70-year-old retired soldier with type 2 diabetes, ischemic heart disease, and hypertension, had been unwell since October 5, 2012, with fever, urinary retention, flank pain, diarrhea, renal colic, and urinary tract infection. On October 13, he was admitted to the hospital with cardiac failure. Six months before admission, he had traveled briefly to Bahrain with two of his sons (Patients 2 and 4) seeking treatment for chronic knee pain. During the hospitalization for the febrile illness, therapy with continuous positive airway pressure (CPAP) was started, and hydrocortisone was added to a regimen of broad-spectrum antibiotics (piperacillin–tazobactam, azithromycin, and trimethoprim–sulfamethoxazole). Chest radiography showed bilateral hilar interstitial infiltrates. With worsening cardiac and renal function, he was transferred to the cardiac critical care unit, where he was intubated for mechanical ventilation and underwent hemodialysis. Microbiologic testing of sputum, endotracheal aspirates, and bronchial-lavage fluids did not identify an infectious cause. On hospital day 9, cardiogenic and septic shock developed, and he died on October 23, 2012.

Patient 2, a 39-year-old Saudi factory worker and the eldest son of Patient 1, presented on October 28, 2012, to the hospital emergency department with a 4-day history of fever, rigors, anorexia, and a cough productive of purulent blood-streaked sputum. He had been started on therapy with oseltamivir 2 days earlier. He was a long-term smoker, with a history of reactive airway disease but no previous hospitalizations. On examination, he was febrile (temperature, 38.9°C), with rales throughout right mid- to lower-lung fields. Chest radiography showed coalescing patchy densities at the base of the right lung (Fig. 2A). Oral azithromycin and parenteral ceftriaxone were added to oseltamivir. The patient's oxygenation improved with CPAP therapy, and he was discharged the following morning. Hours later, he returned to the hospital with acute hypoxemia. Chest radiography showed worsening opacities, and he was admitted directly to the intensive care unit, where he was intubated and treated with broad-spectrum antibiotics and hydrocortisone (Fig. 2B). His condition continued to dete-

riorate over the next 2 days, and he died on November 2, 2012.

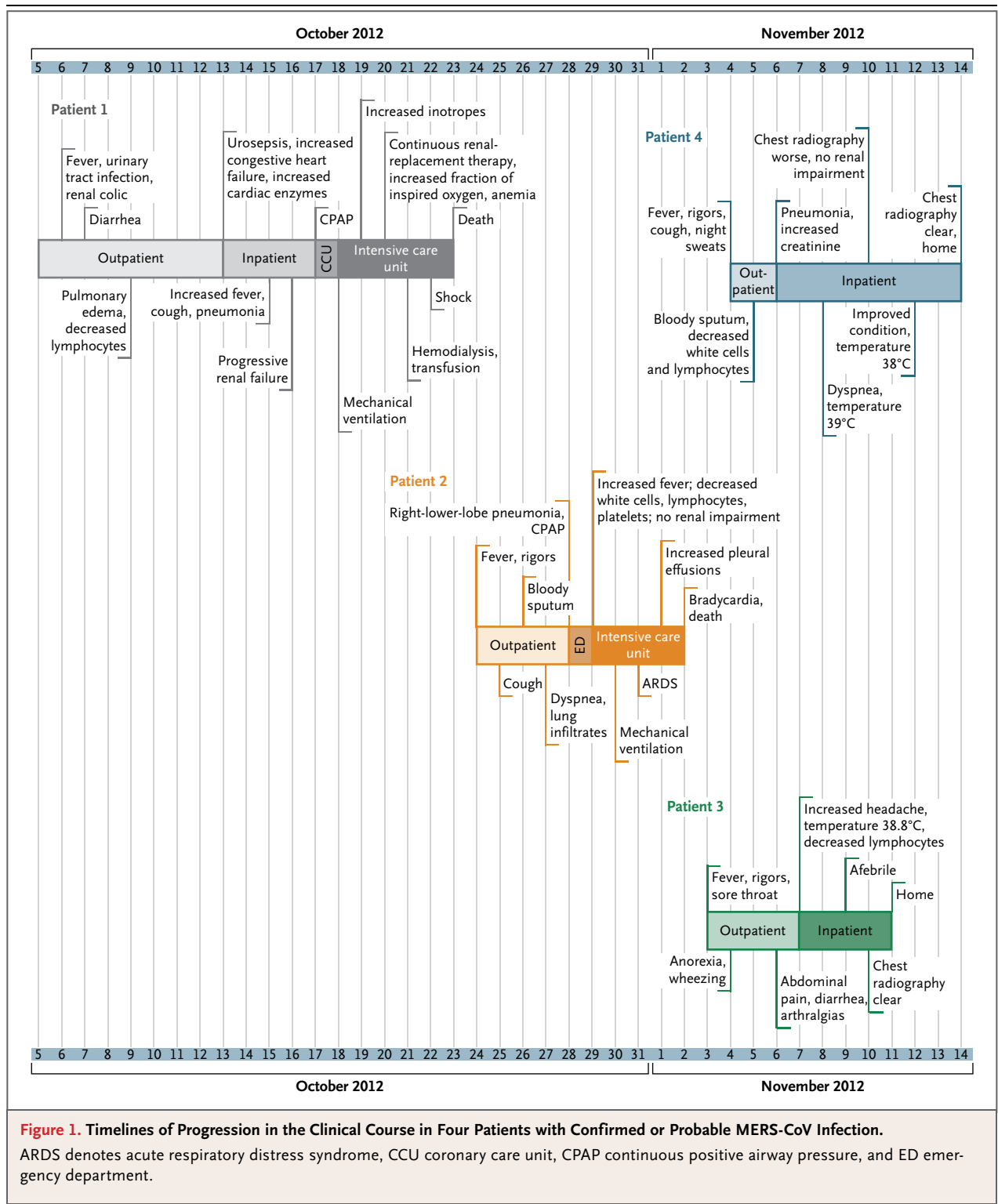
On November 3, 2012, Patient 3, the previously healthy 16-year-old eldest son of Patient 2 and grandson of Patient 1, reported having fever, malaise, sore throat, cough, and wheezing. Over the next 4 days, his symptoms worsened and he became intolerant of food. On November 7, he was admitted to the hospital with a temperature of 38.8°C, watery diarrhea, abdominal pain, myalgia, worsening cough, and headache. Chest radiography showed bilateral hilar infiltrates. Results on testing of routine blood counts, serum electrolytes, and renal and liver function were normal and remained unchanged during his hospitalization. He was treated with oseltamivir, ceftriaxone, and azithromycin. By November 11, the infiltrates had resolved; he was then switched to oral antibiotics and discharged from the hospital.

On November 4, 2012, Patient 4, the 31-year-old younger brother of Patient 2 and son of Patient 1, reported an acute onset of fever, rigors, and night sweats, which were followed by cough productive of blood-streaked sputum. He was a smoker with no other coexisting illnesses and no previous hospital admissions. Although in no acute distress, he was admitted to the hospital on November 6 after chest radiography showed coalescing airspace densities and was treated empirically with oseltamivir, ceftriaxone, azithromycin, and glucocorticoids. Leukopenia was treated with granulocyte colony-stimulating factor (G-CSF). The vital signs remained stable; blood-gas evaluations showed satisfactory oxygen levels while the patient was breathing ambient air. Results on testing of serum electrolytes and renal and liver function and coagulation profiles remained normal. On November 13, all antimicrobial therapy was discontinued, and Patient 4 was discharged home on November 14.

## LABORATORY TESTING AND RESULTS

## VIRAL IDENTIFICATION

Routine clinical laboratory tests for influenza, parainfluenza, and respiratory syncytial viruses, adenovirus, rhinovirus, enterovirus, Epstein–Barr virus, cytomegalovirus, and human metapneumovirus were negative for all four patients. Samples obtained from the patients were also seronegative for human immunodeficiency virus, *Mycoplasma pneumoniae*, and *Chlamydia pneumoniae*; test-

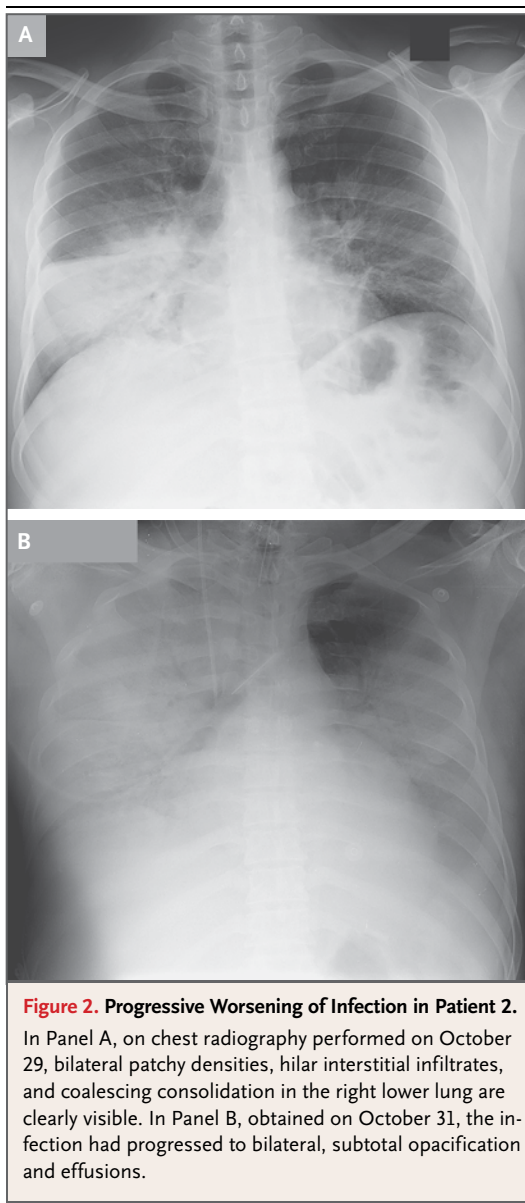


**Figure 1. Timelines of Progression in the Clinical Course in Four Patients with Confirmed or Probable MERS-CoV Infection.**

ARDS denotes acute respiratory distress syndrome, CCU coronary care unit, CPAP continuous positive airway pressure, and ED emergency department.

ing for legionella species was negative for urinary antigen. There was no identification of coinfecting bacteria, mycobacteria, or fungi at baseline or subsequently as a superinfecting process.

MERS-CoV infection was retrospectively confirmed in three of the four patients (Patients 1, 2, and 4) on reverse-transcriptase–polymerase-chain-reaction (RT-PCR) amplification of consensus



**Figure 2. Progressive Worsening of Infection in Patient 2.**

In Panel A, on chest radiography performed on October 29, bilateral patchy densities, hilar interstitial infiltrates, and coalescing consolidation in the right lower lung are clearly visible. In Panel B, obtained on October 31, the infection had progressed to bilateral, subtotal opacification and effusions.

viral RNA targets (upE and ORF1b).<sup>5</sup> Testing was positive for MERS-CoV on bronchial lavage from Patient 1 and on sputum from Patients 2 and 4. Lower-tract specimens were not available for Patient 3, since his illness was mild, and attempts to amplify MERS-CoV genes from upper-tract swabs were not successful. Testing was done at Ministry of Health laboratories in Jeddah, Saudi Arabia, and by United Kingdom Health Protection Agency laboratories in Birmingham and Colindale.

Serologic data are not available for the patients or their contacts. New serologic and im-

munofluorescence tests developed specifically for MERS-CoV have yet to be validated for sensitivity and specificity.

#### FAMILY AND HOSPITAL CONTACTS

The four patients were members of a Saudi extended family. Patient 1 and his 2 sons (Patients 2 and 4) were married and lived in separate apartments within one large house located in the southern area of Riyadh. A total of 28 persons lived in this extended household, including 9 children under the age of 14 years. Aside from the 4 patients included in this report, no other family members had major respiratory symptoms or illness from September 2012 through April 2013. This home is flanked by similar buildings on either side and is remote from any rural enterprises. There were no domestic animals in the immediate vicinity of the home, and the family did not keep pets. The only animal exposure occurred with Patient 4, who attended the slaughtering of a camel on October 24. No one had traveled out of Riyadh in the previous 3 months. Contact among family members was frequent but occurred most often between husbands and wives and their children (Table 1).

All adult and adolescent male family members shared meals together and ate separately from female relations and their young children. The men also socialized and visited the local mosque together. Twelve family members of Patient 1 occupied a large upstairs apartment; older sons also shared space downstairs. Patient 3 lived with his parents in an upstairs apartment shared with seven siblings between the ages of 2 and 18 years. Patient 4, his wife, and two children lived in a downstairs apartment. Another newly married brother occupied a separate downstairs unit. Married daughters and their young children were frequent visitors to the home, as were cousins who lived in the immediate neighborhood.

After the onset of illness and before hospital admissions, each patient was cared for at home by family members; wives were the primary caregivers for the married men, and 16-year-old Patient 3 was cared for by his mother and sisters. The duration of the prehospital illness varied for each patient: 10 days for Patient 1, 4 days for Patient 2, 5 days for Patient 3, and 3 days for Patient 4. As head of the family, Patient 1 also had frequent contact with his two older sons, Patients 2 and 4, during the onset of the illness.

**Table 1. Level of Contact among Family Members of Patients with MERS-CoV Infection before and after Hospital Admission.\***

Family Member	Close Contact with Patient 1 before Admission	Close Contact with Patient 1 after Admission	Close Contact with Patient 2 before Admission	Close Contact with Patient 4 before Admission	Clinical Diagnosis of MERS-CoV Infection
Wife of Patient 1	Frequent	No	Infrequent	Infrequent	No
Patient 2	Frequent	Frequent	NA	Frequent	Yes
Wife of Patient 2	No	No	Frequent	No	No
Patient 3	Infrequent	Infrequent	Frequent	Frequent	Yes
Patient 4	Frequent	Frequent	Frequent	NA	Yes
Wife of Patient 4	No	No	No	Frequent	No

\* NA denotes not applicable.

Once hospitalized, these elder sons, in particular Patient 2, spent many hours at his bedside tending to his personal welfare.

A total of 124 health care workers who had contact with the patients remained healthy as of January 2013.

## DISCUSSION

Here we describe a family cluster of three confirmed cases and one probable case of MERS-CoV infection, using the case definition<sup>5</sup> as reported to the WHO in November 2012. All four male patients ranged in age from 16 to 70 years. The male preponderance of the viral illness in this family cluster remains to be explained. The case progressions shown in Figure 1 suggest that two of the three confirmed infections (in Patients 2 and 4) were probably secondary cases. The third probable case (in Patient 3) may have been either a secondary or a tertiary infection. There were two deaths: the index patient, an elderly man who had a number of coexisting illnesses, and a previously healthy young man. Both had severe pneumonia; the index patient also had renal failure. Of the two survivors, one had lobar pneumonia that did not progress, along with lymphocytopenia and thrombocytopenia, both of which resolved. One probable case (in Patient 3), a previously healthy adolescent, had a typical flu-like presentation plus radiologic evidence of a lung infection, which did not progress to severe pneumonia.

Viral loads in patients with SARS-CoV infection were reported to be highest in the respiratory tract 10 days after the onset of symptoms, and shedding of virus in stool peaked on day 13.<sup>6</sup> This may explain the success of classic infection-

control interventions in averting hospital outbreaks of SARS-CoV infection. In addition, elderly patients with SARS who had coexisting illnesses, a long duration of illness, and an atypical presentation transmitted infection more often than did younger patients or those with acute pneumonia. In the family case cluster in our study, there was a similar pattern of illness associated with MERS-CoV. Although it is not possible to exclude a single common source of infection, Patient 2 appears to have acquired the infection from his father, perhaps after the father was hospitalized. The source of infection for Patients 3 and 4 is less obvious; they may have had either secondary infection contracted from Patient 1 or tertiary infection contracted from Patient 2. Patient 3 shared his father's apartment and was less exposed to his ill grandfather than he was to his father, Patient 2.

None of the family's female caregivers reported having a major respiratory illness from September 2012 through January 2013, though each had repeated close contact with ill family members before their hospitalizations. This finding may suggest that there is a reduced risk of disease transmission during the early stages of infection with MERS-CoV. Female family members did not visit their male relatives with any frequency once they were hospitalized. Nine children under the age of 14 years shared the house, and none became ill. Again, their exposures came before the hospitalizations of their relatives.

It is unclear when or how the presumed index case, Patient 1, might have become infected. The source of MERS-CoV is being investigated in animal reservoirs, but none has been found to date. Patient 1's outpatient course was atypical and protracted, as compared with secondary ill-

ness in his sons and grandson. The disease onset and presentation may have been confounded by preexisting heart failure and pulmonary edema. After he was admitted to the hospital, progressive severe pneumonia and multiorgan failure rapidly developed.

All four patients had similar symptoms at the onset of infection, plus early evidence of an evolving respiratory focus. Symptoms at onset included a temperature of more than 38°C, rigors, and malaise, followed by cough, myalgia, and headache. Productive cough with purulent, blood-streaked sputum and exertional dyspnea appeared early in the course of illness for Patients 2 and 4, whereas it developed later in Patient 1, and recognition was confounded by preexisting pulmonary edema. Patient 2 progressed rapidly to severe pneumonia and hypoxia and the need for mechanical ventilation. Neither patient who underwent mechanical ventilation survived. Patient 3 had radiographic evidence of lung involvement, but his symptoms remained mild throughout the hospital course. Despite having lobar pneumonia, Patient 4 did not have hypoxia.

Acute renal failure requiring hemodialysis was identified in two earlier Saudi patients with confirmed MERS-CoV infection.<sup>1,7</sup> However, in the family cluster reported here, only Patient 1, whose illness was prolonged and lung disease severe, had renal failure, with renal function that was compromised on admission. After subsequent progression to renal failure, he was treated with regular hemodialysis. Patient 2 may have had similarly impaired renal function, but he died of fulminant pneumonia.

Three of the four patients had gastrointestinal symptoms: anorexia, abdominal pain, and diarrhea. This complex of symptoms was also shared by patients with SARS, albeit by a minority. Viral shedding in feces was ultimately important in understanding the epidemiologic features of SARS CoV infection in Hong Kong.<sup>8</sup>

Hematologic abnormalities, in particular lymphocytopenia, had been identified as a clinical feature in patients with SARS.<sup>9</sup> Three of the four patients in this cluster were similarly affected: Patients 2 and 4 both had lymphocytopenia before hospital admission, and Patient 4 had progression to thrombocytopenia and neutropenia, which was treated with G-CSF. Patient 1 had unexplained anemia requiring multiple transfu-

sions during the late course of his illness. Of interest, Patient 3 had transient but moderately severe pain in both knees and lower back, which resolved as fever and respiratory symptoms abated, suggesting a possible immune-complex-mediated process.

An atypical presentation and prolonged outpatient course for the index case meant that all 27 members of this large family were exposed. Although 3 other family members became ill, 24 did not. Three women in the family had repeated face-to-face contact with the patients before hospitalization; all the women remained well, whereas 2 male family members who attended the index patient before and during hospitalization acquired the infection. Although this suggests that MERS-CoV, like SARS-CoV, is not readily transmitted early in the illness, other coronaviruses (e.g., HCoV-229E, HCoV-NL63, and HCoV-OC43) appear to be transmitted earlier in the course of disease. Another explanation is that the index patient acquired the infection during hospitalization.

The family cluster cases describe a disease spectrum that includes an atypical presentation by the index patient, severe disease and death in one previously healthy young contact, and milder illness in two other young family members who were close contacts. Relatives and health staff contacts have remained healthy for the past 6 months. Table 2 shows some clinical features of MERS-CoV infection as compared with features of SARS-CoV infection: abrupt onset of high fever, rigors, and malaise, which progress to a productive cough and pneumonia. Three of the four patients in this cluster had gastrointestinal symptoms, and two had diarrhea. Hemodialysis was required only for the index patient, who had preexisting chronic illness; one other patient had an elevated creatinine level on admission. Lymphocytopenia, another prominent feature of SARS-CoV infection, was found in three of the four patients and in the two patients whose cases have been published previously. Chest radiography of all patients showed lung infiltrates soon after symptom onset; three of the four patients with progression to pneumonia had airspace disease, in contrast with patients with SARS-CoV pulmonary infection, who more often had atypical pneumonias that were characterized by interstitial infiltrates.

This report suggests that transmission of MERS-CoV occurred among family members but

**Table 2. Clinical Findings and Test Results in Two Patients in Saudi Arabia and Four Patients in the Family Cluster with Confirmed or Probable MERS-CoV Infection, as Compared with Patients with SARS-CoV Infection.\***

Findings and Test Results	Patient in Bisha <sup>1</sup>	Patient in Riyadh <sup>10</sup>	Patient 1	Patient 2	Patient 3	Patient 4	Patients with SARS <sup>4</sup> % with condition
Presenting symptoms							
Temperature >38°C	+	+	+	+	+	+	94–100
Chills or rigors	+	+	+	+	+	+	65–73
Cough	+	+	+	+	+	+	69–78
Headache	NA	+	+	+	+	+	20–50
Myalgia	NA	+	+	+	+	–	50–60
Malaise	NA	+	+	+	+	+	30–50
Dyspnea	+	+	+	+	–	+	20–30
Diarrhea or other gastrointestinal symptom	NA	–	+	+	+	–	10–30
Test results on admission							
Infiltrates on chest radiography	+	+	+	+	+	+	94–100
Leukopenia (<4.0×10 <sup>3</sup> /mm <sup>3</sup> )	–	–	+	+	–	+	25–35
Lymphocytopenia (<1.5×10 <sup>3</sup> /mm <sup>3</sup> )	+	+	+	+	+	+	68–70
Platelet count <140×10 <sup>3</sup> /mm <sup>3</sup>	+	–	–	+	–	+	40–45
Elevated lactate dehydrogenase	NA	+	+	NA	NA	NA	50–71
Elevated alanine aminotransferase	NA	+	–	–	–	–	20–30
Elevated troponin	NA	–	+	NA	NA	NA	NA
Elevated urea	–	+	+	–	–	+	NA
Elevated creatinine	–	+	+	–	–	+	NA
Albumin <35 g/liter	NA	–	+	NA	NA	–	NA
During hospitalization							
Mechanical ventilation	+	+	+	+	–	–	NA
Elevated urea	+	+	+	–	–	–	NA
Elevated creatinine	+	+	+	–	–	–	NA
Hemodialysis	+	+	+	–	–	–	NA
Diagnosis of coexisting illness	–	+	+	–	–	–	NA
Survival	–	+	–	–	+	+	NA

\* Plus indicates yes, and minus indicates no. NA denotes not available.

indicates that the risk of MERS-CoV infection among close contacts of patients is low, although infection risk is increased in patients with immunosuppression or coexisting illnesses. As of May 28, 2013, a total of 49 confirmed cases of MERS-CoV infection with 26 deaths (53% case fatality rate) have been reported to the WHO<sup>2</sup>: 37 in Saudi Arabia (with 21 deaths), 2 in Jordan (with 2 deaths), 4 in the United Kingdom (with 2 deaths), 2 in Germany (with 1 death), 2 in France (with no deaths), and 2 in Tunisia (with

no deaths). Current global concern rests on the ability of MERS-CoV to cause major illness among the close contacts of patients, particularly in family members, work colleagues, and health care workers. Serologic studies are required to further define the epidemiologic features, infectivity among asymptomatic contacts, and prevalence in the community of MERS-CoV. The finding of gastrointestinal symptoms in three of the four patients in this study may be an important finding for MERS-CoV epidemiology, hospital infec-

tion-control measures, and contact isolation. Further studies on shedding of MERS-CoV in stool and introduction of the use of rectal swabs and stool for detection of MERS-CoV are required.

Routine MERS-CoV testing of all patients with severe pneumonia is now ongoing in Saudi Arabia. Serologic testing of close contacts of patients with this disease will help to define local transmission rates and risk factors. Until now, data on MERS-CoV cases were not sought outside the Arabian Peninsula because of restrictions in the initial WHO case definition for screening for the presence of MERS-CoV. The latest WHO interim surveillance guidelines (revised on March 18, 2013) have removed this geographic restriction<sup>10</sup> and will enable screening over a wider geographic area, which will allow for a more accurate definition of the epidemiologic features of MERS-CoV infection. Several major research challenges remain: rapid

detection and prevention of new cases through the development and use of rapid, point-of-care diagnostics,<sup>11</sup> the performance of viral sequencing and genomic studies, and the identification of the source of MERS-CoV. To achieve these goals, more coordinated international collaboration and sharing of clinical and research data and other information are urgently required.

Although current data indicate that MERS-CoV does not appear to be as readily transmissible among humans, as was observed with the SARS-CoV epidemic in 2003, continued risk assessment, surveillance, and vigilance by all countries are required.<sup>6</sup> A high degree of clinical awareness is required regarding the possibility of MERS-CoV infection in patients with respiratory infections who have visited the Middle East in the preceding 10 days.

Disclosure forms provided by the authors are available with the full text of this article at NEJM.org.

#### REFERENCES

1. Zaki AM, van Boheemen S, Bestebroer TM, Osterhaus ADME, Fouchier RAM. Isolation of a novel coronavirus from a man with pneumonia in Saudi Arabia. *N Engl J Med* 2012;367:1814-20.
2. ProMED. MERS-CoV—Eastern Mediterranean (06) (<http://www.promedmail.org/>).
3. Genetic sequence information for scientists about the novel coronavirus 2012. London: Health Protection Agency, 2012 (<http://www.hpa.org.uk/Topics/InfectiousDiseases/InfectionsAZ/NovelCoronavirus/respPartialgeneticsequenceofnovelcoronavirus/>).
4. World Health Organization. WHO final summary: SARS. August 15, 2003 ([http://www.who.int/csr/sars/country/2003\\_08\\_15/en/index.html](http://www.who.int/csr/sars/country/2003_08_15/en/index.html)).
5. Corman VM, Eckerle I, Bleicker T, et al. Detection of a novel human coronavirus by real-time reverse-transcription polymerase chain reaction. *Euro Surveill* 2012; 17. abstract.
6. Peiris JS, Chu CM, Cheng VC, et al. Clinical progression and viral load in a community outbreak of coronavirus-associated SARS pneumonia: a prospective study. *Lancet* 2003;361:1767-72.
7. Albarrak AM, Stephens GM, Hewson R, Memish ZA. Recovery from severe novel coronavirus infection. *Saudi Med J* 2012;33:1265-9.
8. Clinical presentation and diagnosis. In: Hoffman C, Kamps S. SARS reference – 10/2003. 3rd ed. Flying Publisher, October 2003 (<http://www.SARSreference.com>).
9. Wong RS, Wu A, To KF, et al. Haematological manifestations in patients with severe acute respiratory syndrome: retrospective analysis. *BMJ* 2003;326:1358-62.
10. World Health Organization. Interim surveillance recommendations for human infection with novel coronavirus as of 18 March 2013 ([http://www.who.int/csr/disease/coronavirus\\_infections/InterimRevisedSurveillanceRecommendations\\_nCoVinfection\\_18Mar13.pdf](http://www.who.int/csr/disease/coronavirus_infections/InterimRevisedSurveillanceRecommendations_nCoVinfection_18Mar13.pdf)).
11. Zumla A, Gant V, Bates M, Mwaba P, Memish ZA. Rapid diagnostic urgently needed for killer infections. *Lancet Resp Med* 2013 May 20 [Epub ahead of print].

Copyright © 2013 Massachusetts Medical Society.